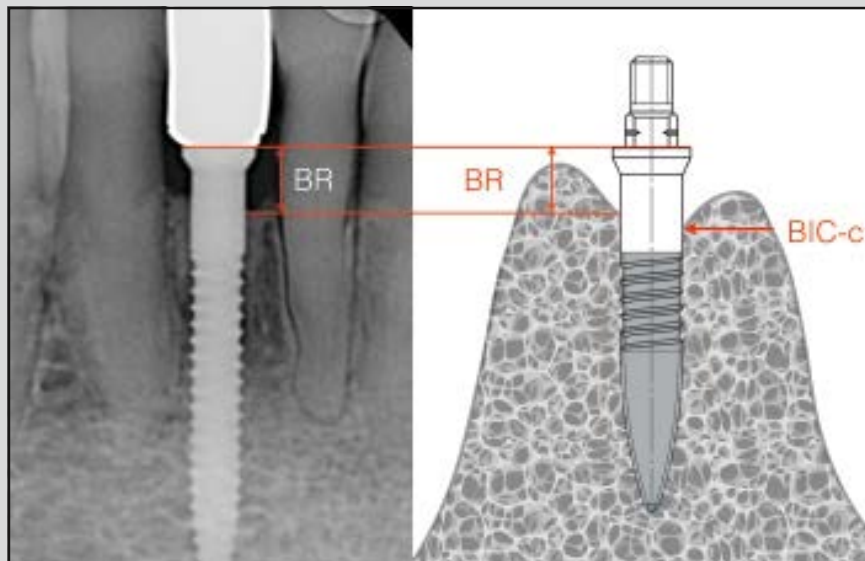
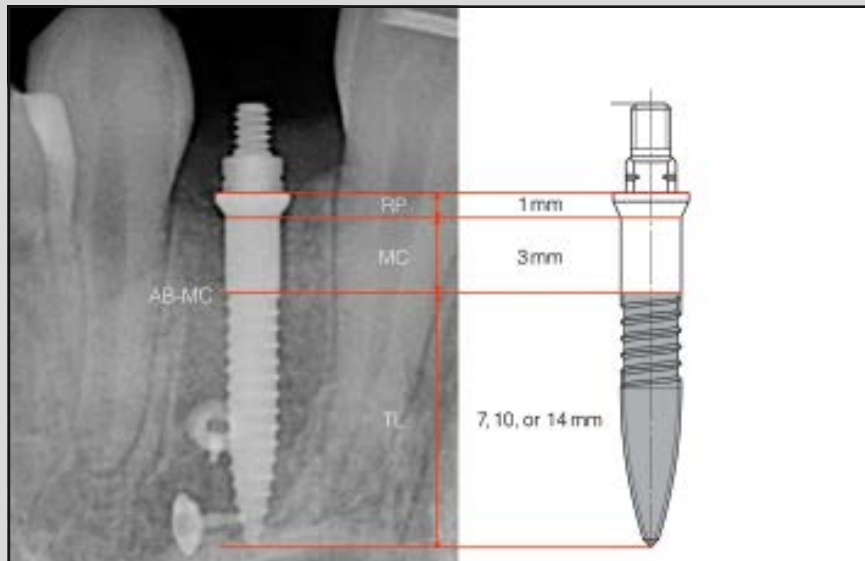
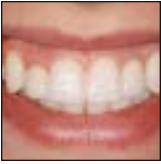Long-Term Retrospective Evaluation of Success of Narrow-Diameter Implants in Esthetic Areas: A Consecutive Case Series with 3 to 14 Years Follow-up



Stuart J. Froum, DDS¹
 Ye Shi, DDS²
 Francois Fisselier, DDS³
 Sang-Choon Cho, DDS⁴

This retrospective study reports on the outcome of 19 narrow-diameter implants (NDIs) placed in 14 consecutively treated patients 3 to 14 years postloading. Peri-implant bone remodeling, bone loss, esthetic outcomes, and patient satisfaction with the final restoration were evaluated. No implant failures or prosthetic complications were reported, yielding a 100% survival rate and a 84.2% success rate. All 14 patients reported that they were very satisfied with the esthetic results. The average mesial and distal bone remodeling was 1.99 mm and 1.84 mm, respectively. This represents physiologic bone loss post-implant placement. Only 5 implants presented with bone loss, producing an average mesial and distal bone loss of 0.14 mm and 0.17 mm, respectively. Bone loss was measured on the threads of the implant from the time of restoration to the time of follow-up. The bone loss did not exceed 0.2 mm per year on any implant. These screw-retained NDIs present a cost-effective, esthetically acceptable alternative for restoring limited spaces in the anterior esthetic zone.

Int J Periodontics Restorative Dent 2017;37:629–637. doi: 10.11607/prd.3266

Dental implant restorations have been documented to have a high degree of success for restoration of completely and partially edentulous patients.^{1,2} A requirement for implant placement is the presence of adequate bone volume and sufficient interdental space to allow standard-diameter implants to be inserted. Procedures have been used to increase facial-lingual bone volume.^{3,4} However, grafting cannot solve mesial-distal space problems. Smaller-diameter implants (3.0 to 3.5 mm) require a minimum mesiodistal space of 6.0 to 6.5 mm to allow adequate implant-tooth distance.^{5,6} Narrow-diameter implants (NDIs) with diameters of < 3 mm were introduced by several implant companies as transitional implants that would allow patients undergoing implant therapy to avoid removable provisional dentures.⁷ According to a systematic literature review, implants with diameters of < 3 mm were classified as NDI category 1.⁸ The implants used in the present study (ANEW, Dentatus) fall into this category, with diameters of 1.8, 2.2, and 2.4 mm and thread lengths of 7, 10, and 14 mm. In 2007, Froum et al⁹ reported 100% survival of 48 implants in 27 patients who received NDIs as permanent implants with 1 to 5 years loading. A systematic review by Klein et al⁸ reported a 90.9% to 100% survival rate for NDIs

¹Clinical Professor and Director of Clinical Research, Ashman Department of Periodontology and Implant Dentistry, New York University College of Dentistry, New York, New York, USA.

²Implant Fellow, Ashman Department of Periodontology and Implant Dentistry, New York University College of Dentistry, New York, New York, USA.

³Clinical Instructor, Prosthodontics Department, Tufts University School of Dental Medicine, Boston, Massachusetts, USA.

⁴Clinical Assistant Professor and Director of Advanced Program for International Dentists in Implant Dentistry and Co-Director of Clinical Research, Ashman Department of Periodontology and Implant Dentistry, New York University College of Dentistry, New York, New York, USA.

Correspondence to: Dr Stuart Froum, 17 W 54th Street, Suite 1C/D, New York, NY 10019, USA. Fax: 212-246-7599. Email: dr.froum@verizon.net

©2017 by Quintessence Publishing Co Inc.

(category 1) over a 12- to 64-month mean range of follow-up. However, success rates of these implants as determined by clinical success parameters (implant in function, no signs of peri-implantitis, no mobility, and excellent esthetic outcomes) have been reported in only 1 of the 10 articles reviewed in the < 3 mm diameter category. The success rate reported was 92.9% in a prospective 3-year study of implants supporting a mandibular overdenture.¹⁰

In clinical cases with missing maxillary lateral incisors or in the mandibular incisor area where there is limited mesiodistal space for standard or reduced diameter implants, a NDI is often the only implant treatment option. The purpose of this case series was to evaluate implant survival and long-term esthetic outcomes including marginal bone level changes, marginal recession, and presence of interproximal papillae for NDIs in the maxillary and mandibular anterior areas. Prosthetic complications and patient satisfaction with the restorations were also evaluated.

Materials and Methods

Clinical data in this study extracted as deidentified information from the routine treatment of patients at the Ashman Department of Periodontology and Implant Dentistry at New York University College of Dentistry (NYUCD). The implant database (ID) was certified by the Office of Quality Assurance at NYUCD. This study was in compliance with the Health Insurance Portability and

Accountability Act requirements and received Institutional Review Board approval (H12209-01-A).

A total of 14 consecutively treated patients who had received NDIs in anterior maxillary or mandibular areas were evaluated to determine bone levels, facial marginal mucosal levels, and papillary changes 3 to 14 years following insertion of the final restorations. The number of patients was set at 14 for feasibility of follow-up. Previous orthodontic and/or bone augmentation procedures of the implant site were recorded. All measurements were performed by two calibrated examiners who were not part of the surgical team that placed or restored the NDIs. This calibration was accomplished by the two examiners meeting separately and together on four separate occasions until the measurements on several sample radiographs were identical to the nearest 0.1 mm.

A radiographic evaluation was conducted to determine the average mesial and distal bone remodeling and bone loss around the NDIs. To evaluate bone loss on nonstandardized periapical radiographs, the known length of the NDI was used for measurement calibration. Measurements on the digital radiographs were made to the nearest 0.1 mm using the x-ray software (DEXIS). The NDIs included in the present study had a 3-mm machined collar and 1-mm restorative platform. All implants were placed with a surgical guide made from an ideal wax-up. The accuracy of precise placement was even more important because the NDI prosthesis does not allow an-

gled abutments. All implants were placed with the restorative platform even with the edentulous crest of bone and the machined collar submerged. The distance between the bone-to-implant contact (BIC) on the machined collar to the restorative platform (RP) was defined as peri-implant bone remodeling (BR), while the distance between the BIC on the threads to the apical border of the machined collar (AB-MC) was defined as peri-implant bone loss (BL) (Figs 1 to 3). Bone remodeling is the physiologic bone loss described in the animal model that takes place when the machined implant collar is submerged.¹¹ Bone loss occurs on the implant threads. The bone level on the most recent radiographs was compared to the level at the time of implant placement. Based on these measurements, the average mesial and distal bone remodeling and bone loss, to the nearest 0.01 mm, were calculated for each implant.

To evaluate gingival health, bleeding on probing (BOP) was recorded using light probing around six aspects of the implant. This was recorded as BOP (+) or no BOP (-). An esthetic evaluation was also performed by measuring the changes in facial mucosal levels and assessing the height of the mesial and distal papillae around each of the NDIs. Mucosal recession was determined by measuring the distance from the midbuccal point of the occlusal surface of the final restoration to the level of the midbuccal marginal mucosa with a millimeter probe and comparing this measurement to the same one made at the last follow-up visit. It

Fig 1 Reference points in the radiograph show a distance of 1 mm from restored platform (RP) to machined collar (MC). The apical border of the machined collar (AB-MC) is where the screw portion of the NDI begins. TL = thread length (7, 10, or 14 mm).

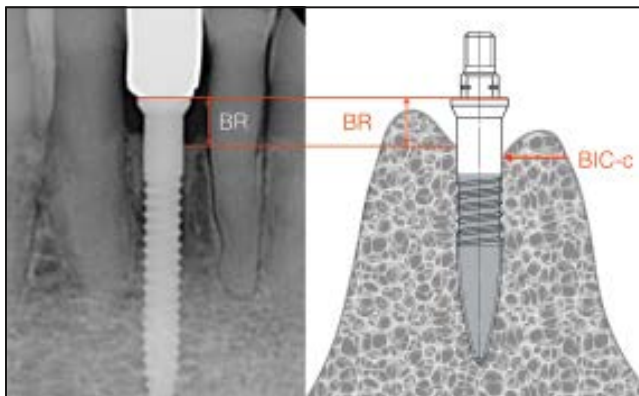
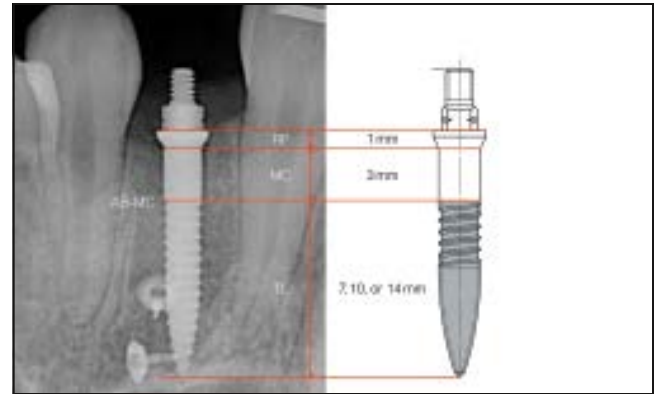


Fig 2 Bone remodeling (BR) occurs from the collar to the apical border of the machined collar. Radiographs of patient 1, NDI 23 showing peri-implant bone remodeling of 1.5 mm mesially and 1.2 mm distally around the machined collar. BIC-c = bone-to-implant contact on the collar.

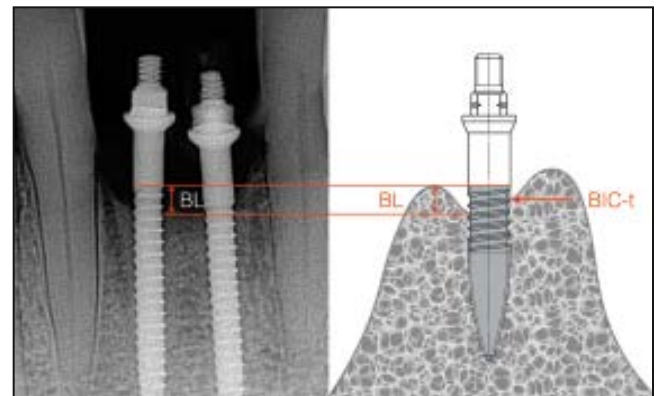


Fig 3 Bone loss (BL) occurs apical to the apical border of the machined collar along the threaded portion of the implant. Radiographs of patient 13, NDI 25 showing peri-implant bone loss of 1.3 mm mesially and 1.1 mm distally around the threads with 11 years follow-up. BIC-t = bone-to-implant contact on the threads.

was then recorded as recession (-), no change in gingival margin (0), or coronal movement of buccal mucosa (+) and rounded to the nearest millimeter. The papilla index score (PIS) was used to determine the status of the interproximal papillae with scores of 0 (no papilla present), 1 (less than half the papilla present), 2 (more than half of the papilla present, but not to the contact point), 3 (papillae completely filling the interproximal space), and 4

(papilla hypertrophy).¹² For the final restorations of all 19 NDIs, the contact point was placed to match the level of the contact points on the adjacent teeth in the anterior area. In some cases, the contact point was lengthened, but in no case was the papillae eliminated (Fig 4).

Each patient had been recalled at 2- to 4-month intervals for maintenance and monitoring. These were described in a previous publication.⁹ Measurements and radiographs

were taken at 6-month intervals. At each of these visits, patients were asked if they were satisfied with the esthetics of the NDI restorations. Responses were recorded as unsatisfied, satisfied, or very satisfied.

When the PIS was 2 or greater, marginal recession was (0) or (+), no BOP was observed, bone loss was < 0.2 mm per year, and the patient was satisfied or very satisfied with the esthetics of the restoration, the implant was classified as successful.¹³

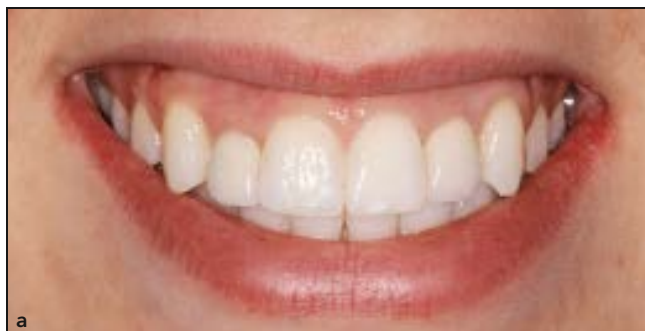
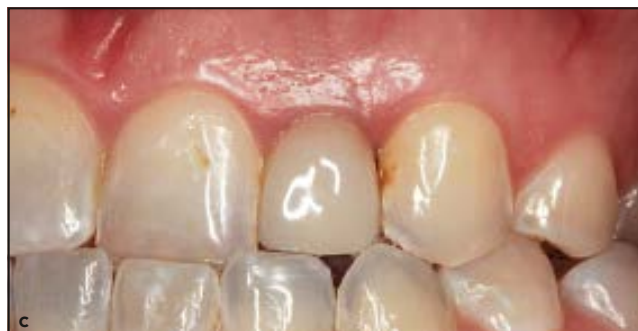
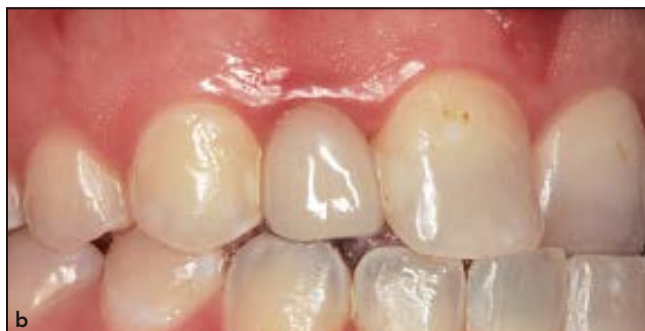Fig 4 Clinical view after final restoration of the maxillary right and left lateral incisors. (a) At the 5-year follow-up. (b) Right lateral incisor at the 11-year follow-up. (c) Left lateral incisor at the 11-year follow-up.



Inclusion Criteria

Patients who met the following criteria were selected for the study:

1. Implant placement required in the maxillary or mandibular anterior area (canine to canine) in a site that was dimensionally inadequate for placement of a standard-diameter implant (≥ 3 mm)
2. The area was edentulous for at least 3 months following extraction
3. Aged at least 17 years and facial growth completed; any orthodontic therapy and/or bone augmentation of the site completed at least 6 months prior to NDI placement

4. Following computerized axial tomographic (CAT) scan evaluation, at least 4.8 mm of distance mesiodistally between adjacent teeth to allow at least 1.2 mm of distance between the NDI restoration (of 1.8, 2.2, or 2.4 mm) and the adjacent natural tooth
5. Dental prophylaxis within 1 month from the time of surgery

4. Severe bruxism and/or clenching
5. Pregnant or intention to become pregnant in the next 2 years
6. Medical conditions or medications taken that would preclude implant placement (eg, uncontrolled diabetes, a history of taking intravenous bisphosphonates or any medication that would affect osseointegration)

Exclusion Criteria

Patients who met the following criteria were excluded from the study:

1. Smoking more than 10 cigarettes per day
2. Untreated periodontitis
3. Active caries

The surgical procedure, postoperative follow-up protocol, and fabrication of the provisional and definitive restorations were described in a previous study.⁹ In the present study, all but six implants were placed with a flapless approach using surgical guides fabricated from an ideal wax-up and made on a vacuum-formed tray. The widest diameter of NDI

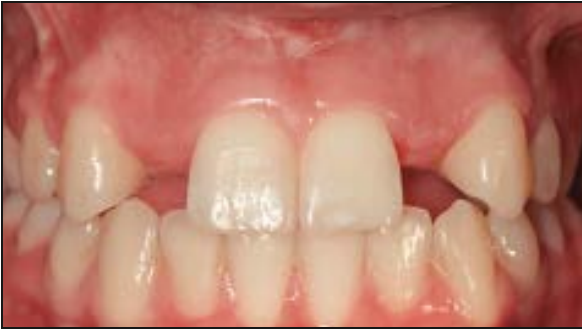

Fig 5 Clinical preoperative view showing missing bilateral maxillary incisors of patient 8.

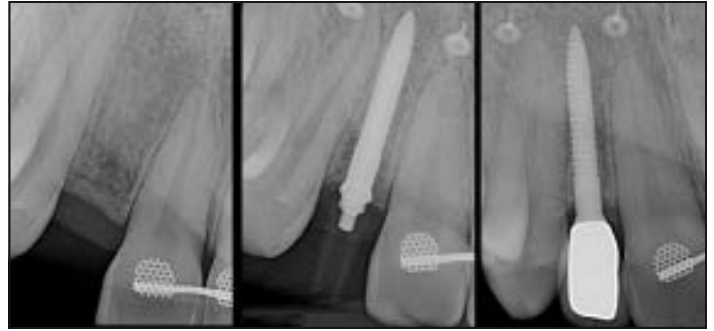


Fig 6 Radiographs of the maxillary right lateral incisor showing the presurgical site (left), immediate post NDI placement (center), and 5-year follow-up (right) with peri-implant mesial and distal bone remodeling of 1.3 and 1.4 mm, respectively, without bone loss.

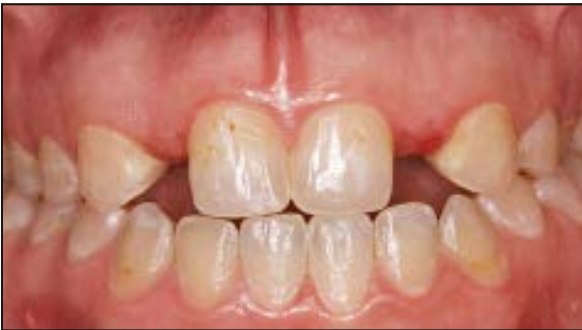

Fig 7 Clinical preoperative view showing limited space in the maxillary right and left lateral incisor areas of patient 5.

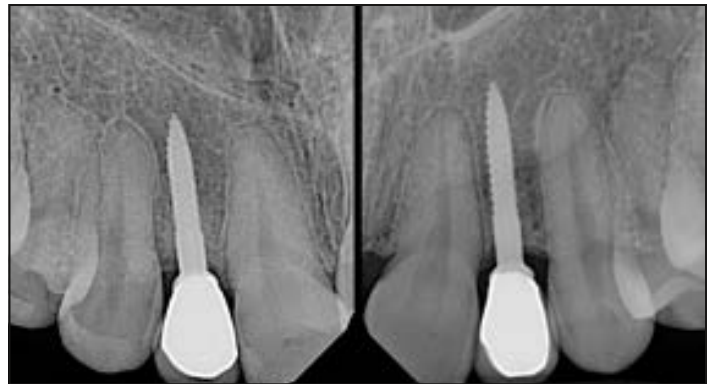

Fig 8 Radiographs at 11 years following NDI restorations showing peri-implant bone remodeling around the right lateral incisor of 1.6 mm mesially and 1.4 mm distally (left), and around the left lateral incisor (right) of 0.90 mm mesially and 0.50 mm distally, without bone loss on either implant.

(1.8, 2.2, or 2.4 mm) was selected to allow at least 1.2 mm between the NDI and adjacent tooth. The longest NDI (7, 10, or 14 mm) that would fit entirely in bone according to the CT scan and would avoid any vital anatomy or cause a fenestration or dehiscence was selected.

Results

In this case series, study subjects included 14 patients, of whom 6

were men and 8 were women, aged 23 to 87 years (average 48.6 years). Of the 19 implants placed, 10 were in the mandibular incisor area and 7 were in the maxillary right and/or left lateral incisor area. Of the 14 patients, 4 had received orthodontic therapy and 2 had received bone augmentation procedures to increase buccal-lingual dimension. When performed, these procedures were completed at a minimum of 6 months prior to implant placement. Of the 14 patients, 3 were smokers

(< 10 cigarettes per day) and 3 had history of periodontitis, while 2 had a history of hypertension and one of these also had a history of diabetes (Type II). These conditions were well controlled, and medical clearance was obtained prior to treatment. These 14 consecutively treated patients received 19 screw-retained NDIs, which were loaded for periods of 3 to 14 years postinsertion (Figs 4 to 11). No implants or prostheses were lost or replaced during the follow-up period.

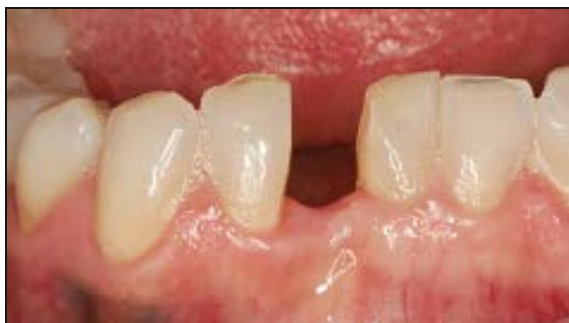

Fig 9 Clinical preoperative view of missing mandibular right central incisor of patient 10.

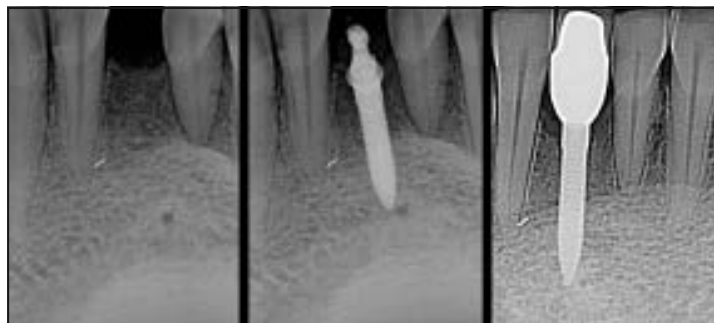

Fig 10 Presurgical site (left), immediate post NDI placement (center), and 6-year follow-up (right) radiographs showing peri-implant bone loss of 0.4 mm mesially and 0.6 mm distally.

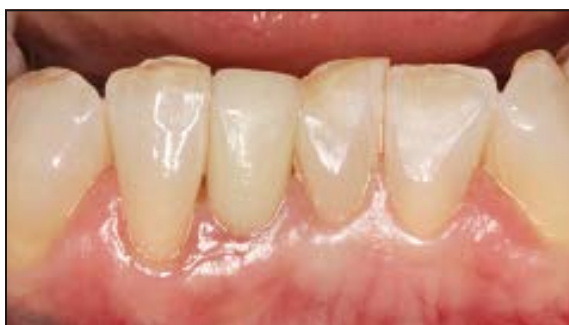

Fig 11 Clinical view of the NDI restoration 6 years postrestoration.

No surgical or prosthetic complications were reported with any of the 19 NDIs. In the present study, the average mesial remodeling around the submerged machined collar was 1.99 mm (range: 0.20–4.00 mm), while the average distal bone remodeling was 1.84 mm (range: 0.10–4.00 mm). Of the 19 implants, only 5 (8 sites) presented with bone loss around the threads, equating to an average mesial and distal bone loss of 0.14 mm and 0.17 mm, respectively. Of the 5 implants that showed bone loss, none exceeded 0.2 mm per year based on the length of follow-up.

The average mesial PIS was 2.47, and the average distal PIS was 2.58. Of 19 implants evaluated for buccal marginal mucosal recession, 3 showed 1 mm recession, 14 showed no recession, and 2 showed 1 mm coronal movement of the buccal mucosa. Bleeding on probing was reported on 3 of the 19 NDIs.

All 14 patients reported that they were very satisfied with the esthetic outcome of their treatment (Table 1).

Of the 19 implants, 3 showed 1 mm of marginal recession and had a PIS < 2 and BOP (+). Therefore, 16 of the 19 implants evaluated satisfied

the study implant success criteria, producing a success rate of 84.2%.

Discussion

The implant and implant/restoration survival rates in this case series were 100% (19/19). These results are comparable to implant survival rates reported in other studies with NDIs.^{9,14} Froum et al⁹ had a 100% survival rate with 48 NDIs over a period of 1 to 5 years. Mazor et al¹⁴ placed 32 implants with only one case of failure due to mechanical overload. Bulard and Vance¹⁵ found a 8.83% failure rate for a period of 6 months

Table 1 Peri-implant Bone Remodeling, Bone Loss, Esthetic Outcomes, and Patient Satisfaction

Patient	Implant site (FDI)	Implant size (mm)	Follow-up (y)	Mesial bone remodeling (mm)	Distal bone remodeling (mm)	Mesial bone loss (mm)	Distal bone loss (mm)	Marginal recession (mm)	BOP	Mesial PIS	Distal PIS	Patient satisfaction
1	32	2.2 × 14	9	1.50	1.20	0.00	0.00	-1	+	1.00	2.00	VS
2	12	2.2 × 10	9	1.50	1.70	0.00	0.00	+1	-	3.00	3.00	VS
3	31	1.8 × 14	9	4.00	4.00	0.30	0.80	0	-	2.00	2.00	VS
	41	1.8 × 14	9	1.80	1.50	0.00	0.00	0	-	2.00	3.00	VS
4	31	2.2 × 10	11	0.20	0.10	0.00	0.00	0	-	3.00	3.00	VS
5	12	1.8 × 10	11	1.60	1.40	0.00	0.00	0	-	3.00	3.00	VS
	22	1.8 × 10	11	0.9	0.50	0.00	0.00	0	-	3.00	3.00	VS
6	22	1.8 × 10	14	1.30	1.40	0.00	0.00	0	-	3.00	3.00	VS
7	42	2.2 × 14	9	0.20	0.90	0.00	0.00	0	-	2.00	3.00	VS
8	12	2.2 × 14	5	1.30	1.40	0.00	0.00	+1	-	3.00	3.00	VS
9	22	2.2 × 14	8	4.00	1.70	0.60	0.00	0	-	3.00	3.00	VS
10	41	2.2 × 10	6	4.00	4.00	0.40	0.60	0	-	2.00	2.00	VS
11	12	2.2 × 10	3	1.90	1.70	0.00	0.00	0	-	3.00	3.00	VS
12	12	1.8 × 14	5	2.10	1.60	0.00	0.00	0	-	3.00	3.00	VS
	22	1.8 × 14	5	1.40	0.70	0.00	0.00	0	-	3.00	3.00	VS
13	31	1.8 × 14	11	2.40	4.00	0.00	0.80	-1	+	2.00	1.00	VS
	41	1.8 × 14	11	4.00	4.00	1.30	1.10	-1	+	1.00	2.00	VS
14	31	2.2 × 10	7	2.10	2.00	0.00	0.00	0	-	3.00	2.00	VS
	41	2.2 × 10	7	1.70	1.20	0.00	0.00	0	-	2.00	2.00	VS
Average				1.99	1.84	0.14	0.17			2.47	2.58	

BOP = bleeding on probing; PIS = Papilla Index score; VS = very satisfied.

to 5 years for 1,029 NDIs. Finally, Vigolo and Givani¹⁶ placed 52 NDIs and had 3 implants fail, for a survival rate of 94.2%. The implant survival rate of the NDIs in present study is also comparable with the implant survival rates (92.6% to 100%) of standard-diameter implants (SDI).¹⁷⁻¹⁹ The success rate (84.2%) of the NDIs in the present study, although lower than those published for SDIs, were based on stricter criteria than were studies reporting the same parameter. The 3-mm machined collar was designed to make plaque re-

moval easier and reduce the risk of peri-implantitis.

Bone remodeling on the submerged machined collar averaged 1.99 mm on the mesial and 1.84 mm on the distal side. This is in accordance with but less than that reported in a histologic study in dogs by Herman et al.¹¹ Of the 19 implants, only 5 (8 sites) presented with bone loss around the threads, which correlated to an average bone loss of 0.02 mm per year on the mesial side and 0.02 mm on the distal. This is considerably less than

the bone loss (0.22 to 0.80 mm) reported for immediately provisionalized narrow- and standard-diameter implants.^{16,20,21} However, with the small sample size in the present study any comparison or conclusions should await further case evaluations and randomized controlled comparison studies. The average mesial PIS of 2.47 and the average distal PIS of 2.58 mm indicated that the NDIs regenerated at least 92.1% of the papilla in all cases (35/38 papillae). Other studies using the PIS to assess implants^{12,22}

Table 2 Indications and Contraindications of Use of NDIs**Indications**

- Narrow ridge with limited buccal-lingual width
- Narrow restorative space with limited mesial-distal width
- Medically compromised patient who is not a candidate for ridge augmentation
- Economically compromised patient
- Immediate loading and provisionalization in esthetic area
- Temporary implant for fixed provisional during ridge augmentation procedure

Contraindications

- Strong occlusal force (implant may be fractured)
- Definitive prosthesis in case of multiple implants requires parallelism (one-piece design limits use of angled abutment)

whose diameters ranged from 3.0 to 3.75 mm, have reported scores from 1.50 to 2.78 with an increase in PIS around the implants at the mesial and distal aspects. Several authors have stated that the papilla level around an implant depends on the underlying supporting peak of interproximal bone, which requires a minimum implant-tooth distance of 1.5 mm.^{6,23,24} In cases where a maxillary lateral incisor or a mandibular incisor is replaced with an implant, the mesial-distal space is often limited to < 6 mm. Therefore, ideal placement of a NDI (with a diameter < 3 mm) is essential to allow maintenance of the underlying peak of bone and consequently the papilla. This is especially critical in cases of patients displaying a high smile line.²⁵ Based on the criteria used to determine success, 16 of the 19 implants (84.2%) were classified as successful. This is similar to but slightly lower than the one study that reported on NDI success.⁹ However, the current study included a longer-term follow-up (3–14 years) compared to the earlier study (1–5 years). No surgical or prosthetic complica-

tions were noted during the present study. In contrast, Vigolo and Givani¹⁶ reported several prosthetic complications. One patient reported the loosening of his custom-screwed post twice. This may be explained by the fact that the screw used in that study was made of plastic (3i Implant Innovation), whereas the screws used in the present case series were made of titanium (Dentatus). In addition, five patients reported fracture or loosening of the provisional resin crowns, and seven patients reported recurrent loosening of provisionally cemented final crowns all with porcelain occlusal surfaces. These problems were avoided in the present study, which used screw-retained restorations and in which the occlusion was adjusted to avoid contact in lateral and protrusive movements.

The NDI system employed in the present study had the advantage of delivering a screw-retained definitive restoration. This provides an option for retrievability, which is extremely useful if the restoration requires replacement because of porcelain fracture or chipping, or if

there is a desire to change the porcelain shade to match the color of the aging adjacent teeth. Based on the survival rate and results of the present and other studies with the same brand of NDIs, specific indications and contraindications can be recommended (Table 2).^{7,9,26,27}

Conclusions

Within the limitations of this case series and with the limited number of subjects, several conclusions can be made. NDIs had a survival rate comparable to standard-diameter implants and demonstrated a reduced annual bone loss. All NDIs achieved favorable esthetic results as reported by all patients in this study, and in cases of limited space, NDIs offer an implant option with the advantages common to standard-implant restorations. The results of the present case series regarding NDI survival and long-term esthetic outcomes are promising, but additional studies with a larger sample of subjects will be required to verify the results reported.

Acknowledgments

The authors reported no conflicts of interest related to this study.

Reference

- Buser D, Mericske-Stern R, Bernard P, et al. Long-term evaluation of non-submerged ITI implants. Part 1: 8-year life table analysis of a prospective multi-center study with 2359 implants. *Clin Oral Implants Research* 1997;8:161–172.
- Pjetursson B, Asgeirsson A, Zwahlen M, Sailer I. Improvements in implant dentistry over the last decade: Comparison of survival and complication rates in older and newer publications. *Int J Oral Maxillofac Implants* 2014;29(suppl):s308–s324.
- Simion M, Scarano A, Gionso L, Piattelli A. Guided bone regeneration using resorbable and nonresorbable membranes: a comparative histologic study in humans. *Int J Oral Maxillofac Implants* 1996;11:735–742.
- Pikos MA. Block autografts for localized ridge augmentation: Part I. The posterior maxilla. *Implant Dent* 1999;8:279–285.
- Grunder U. Stability of the mucosal topography around single-tooth implants and adjacent teeth: 1-year results. *Int J Periodontics Restorative Dent* 2000;20:11–17.
- Tarnow DP, Cho SC, Wallace SS. The effect of inter-implant distance on the height of inter-implant bone crest. *J Periodontol* 2000;71:546–549.
- Froum SJ, Cho SC, Florio S, Misch CM. Use of narrow-diameter implants in treatment of severely atrophic maxillary anterior region with implant-supported fixed restorations. *Compend Contin Educ Dent* 2016;37:334–339.
- Klein MO, Schiegnitz E, Al-Nawas B. Systematic review on success of narrow-diameter dental implants. *Int J Oral Maxillofac Implants* 2014;29(suppl):s43–s54.
- Froum SJ, Cho SC, Cho YS, Elian N, Tarnow DP. Narrow-diameter implants: A restorative option for limited interdental space. *Int J Periodontics Restorative Dent* 2007;27:449–455.
- Elsyad MA, Gebreel AA, Fouad MM, Elshoukoui AH. The clinical and radiographic outcome of immediately loaded mini implants supporting a mandibular overdenture. A 3-year prospective study. *J Oral Rehabil* 2011;38:827–834.
- Hermann JS, Buser D, Schenk RK, Cochran DL. Crestal bone changes around titanium implants. A histometric evaluation of unloaded non-submerged and submerged implants in the canine mandible. *J Periodontol* 2000;71:1412–1424.
- Jemt T. Regeneration of gingival papillae after single-implant treatment. *Int J Periodontics Restorative Dent* 1997;17:326–333.
- Albrektsson T, Zarb G, Worthington P, Eriksson AR. The long-term efficacy of currently used dental implants: A review and proposed criteria of success. *Int J Oral Maxillofac Implants* 1986;1:11–25.
- Mazor Z, Steigmann M, Leshem R, Peleg M. Mini-implants to reconstruct missing teeth in severe ridge deficiency and small interdental space: A 5-year case series. *Implant Dent* 2004;13:336–341.
- Bulard RA, Vance JB. Multi-clinic evaluation using mini-dental implants for long-term denture stabilization: A preliminary biometric evaluation. *Compend Contin Educ Dent* 2005;26:892–897.
- Vigolo P, Givani A. Clinical evaluation of single-tooth mini-implant restorations: A five-year retrospective study. *J Prosthet Dent* 2000;84:50–54.
- Engquist B, Nilson H, Åstrand P. Single-tooth replacement by osseointegrated Brånemark implants. A retrospective study of 82 implants. *Clin Oral Implants Res* 1995;6:238–245.
- Schmitt A, Zarb GA. The longitudinal clinical effectiveness of osseointegrated dental implants for single-tooth replacement. *Int J Prosthodont* 1993;6:197–202.
- Levine RA, Clem DS 3rd, Wilson TG Jr, Higginbottom F, Solnit G. Multicenter retrospective analysis of the ITI implant system used for single-tooth replacements: Results of loading for 2 or more years. *Int J Oral Maxillofac Implants* 1999;14:516–520.
- Kan JY, Rungcharassaeng K, Lozada J. Immediate placement and provisionalization of maxillary anterior single implants: 1-year prospective study. *Int J Oral Maxillofac Implants* 2003;18:31–39.
- Degidi M, Piattelli A, Gehrke P, Felice P, Carinci F. Five-year outcome of 111 immediate nonfunctional single restorations. *J Oral Implantol* 2006;32:277–85.
- Oyama K, Kan JY, Rungcharassaeng K, Lozada J. Immediate provisionalization of 3.0-mm-diameter implants replacing single missing maxillary and mandibular incisors: 1-year prospective study. *Int J Oral Maxillofac Implants* 2012;27:173–180.
- Choquet V, Hermans M, Adriaenssens P, Daelemans P, Tarnow DP, Malevez C. Clinical and radiographic evaluation of the papilla level adjacent to single-tooth dental implants. A retrospective study in the maxillary anterior region. *J Periodontol* 2001;72:1364–1371.
- Kan JY, Rungcharassaeng K, Umezu K, Kojs JC. Dimensions of peri-implant mucosa: An evaluation of maxillary anterior single implants in humans. *J Periodontol* 2003;74:557–562.
- Tjan AH, Miller GD, The JG. Some esthetic factors in a smile. *J Prosthet Dent* 1984;51:24–28.
- Froum SJ, Emtiaz S, Bloom MJ, Scolnick J, Tarnow DP. The use of transitional implants for immediate fixed temporary prostheses in cases of implant restorations. *Pract Periodontics Aesthet Dent* 1998;10:737–746.
- Froum SJ, Simon H, Cho SC, Elian N, Rohrer MD, Tarnow DP. Histologic evaluation of bone-implant contact of immediately loaded transitional implants after 6 to 27 months. *Int J Oral Maxillofac Implants* 2005;20:54–60.