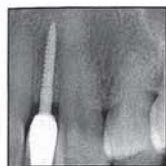

# Expanded Clinical Applications of Narrow-Diameter Implants for Permanent Use



Stuart J. Froum, DDS<sup>1</sup>  
 Mazen Natour, DMD, MScD<sup>2</sup>  
 Sang-Choon Cho, DDS<sup>3</sup>  
 Paul Y. C. Yu, DDS<sup>4</sup>  
 Martin Leung, BDS<sup>4</sup>

*This report discusses the expanded use of narrow-diameter implants (< 3.0-mm diameter) for permanent use and presents multiple clinical uses for supporting permanent restorations. The increased applications of narrow-diameter implants have expanded the options of treatment available to clinicians based on the patients' needs, desires, and limitations. The advantages, disadvantages, indications, and limitations are presented for the use of these narrow-diameter implants for permanent-case scenarios. These implants can serve as a treatment option in cases where standard-diameter implants cannot be placed due to limitations in volume or size of a planned implant site or due to financially or medically compromised patients. Int J Periodontics Restorative Dent 2020;40:529–537. doi: 10.11607/prd.4565*

Standard-diameter implants (3.75- to 4.1-mm-diameter) are being increasingly used in treatment planning for fully and partially edentulous patients.<sup>1</sup> Long-term studies have reported the success of standard-diameter implants with high survival rates, successful osseointegration, and high load-bearing capacities.<sup>2–5</sup> However, standard-diameter implants (SDIs) require sufficient bone height, width, and quality; adequate mesiodistal space; and ample distance from vital structures. Several implant companies have produced lines of narrow-diameter implants (NDIs; 2.9 to 3.3 mm) to try to overcome the space limitations in edentulous areas, but in many cases, even implants of these diameters may be too large to place in areas with limited space. When alveolar width is limited or force factors are compromised, bone augmentation may be performed to allow for a 1-mm increase of implant diameter.<sup>6</sup> However, bone augmentation and guided bone regeneration are not solutions when space is limited in the mandibular incisor or maxillary lateral incisor areas. Moreover, the cost of SDI placement requiring augmentation procedures may be prohibitive for some patients. In addition, a patient's complex medical history can be a contraindication for invasive augmentation procedures. This would include patients with various

<sup>1</sup>Ashman Department of Periodontology and Implant Dentistry, New York University College of Dentistry, New York, New York; Private practice, New York, New York, USA.

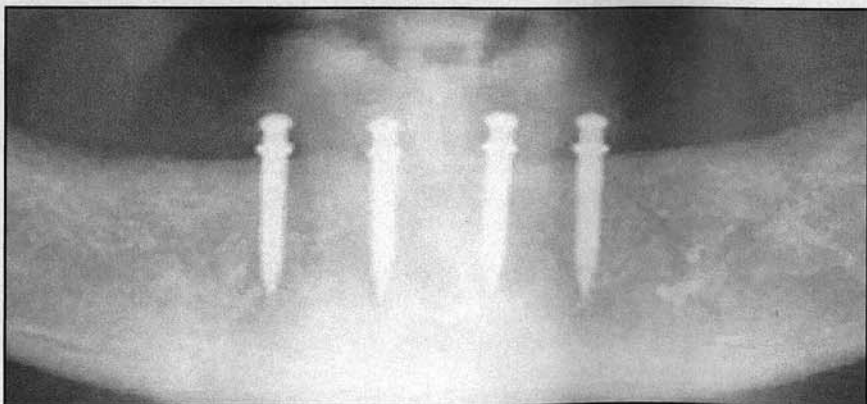
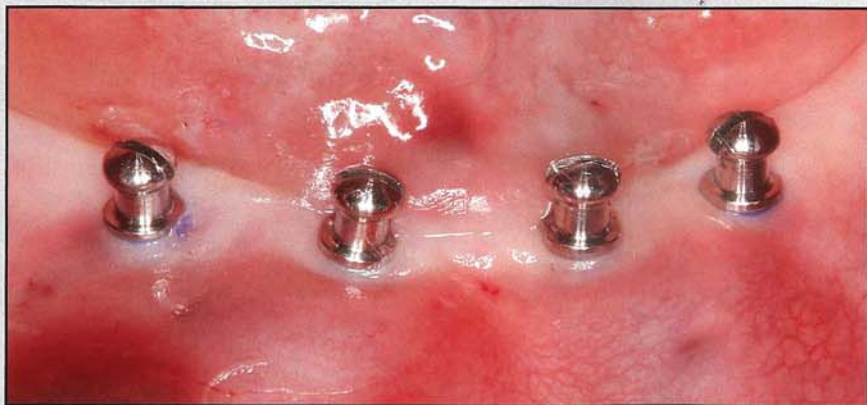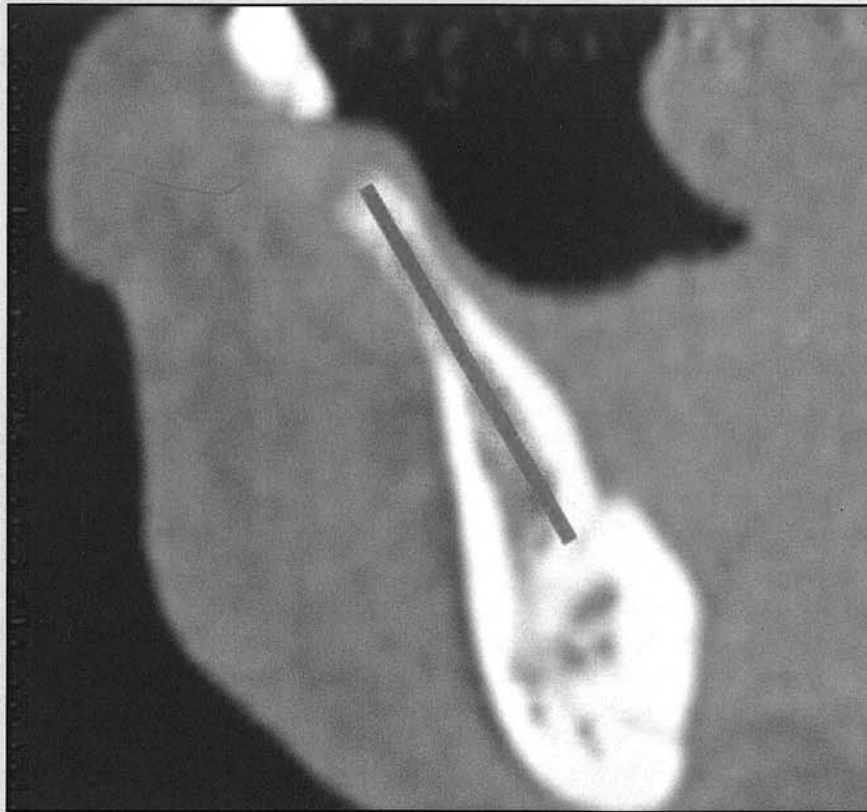
<sup>2</sup>International Congress of Oral Implantologists; Ashman Department of Periodontology and Implant Dentistry, Implant Honors Program, New York University College of Dentistry, New York, New York; Private practice, New York, New York, USA.

<sup>3</sup>Advanced Program for International Dentists in Implant Dentistry, Ashman Department of Periodontology and Implant Dentistry, New York University College of Dentistry, Chairman of IDREF (ICOI) Scientific Advisory Board, New York, New York, USA.

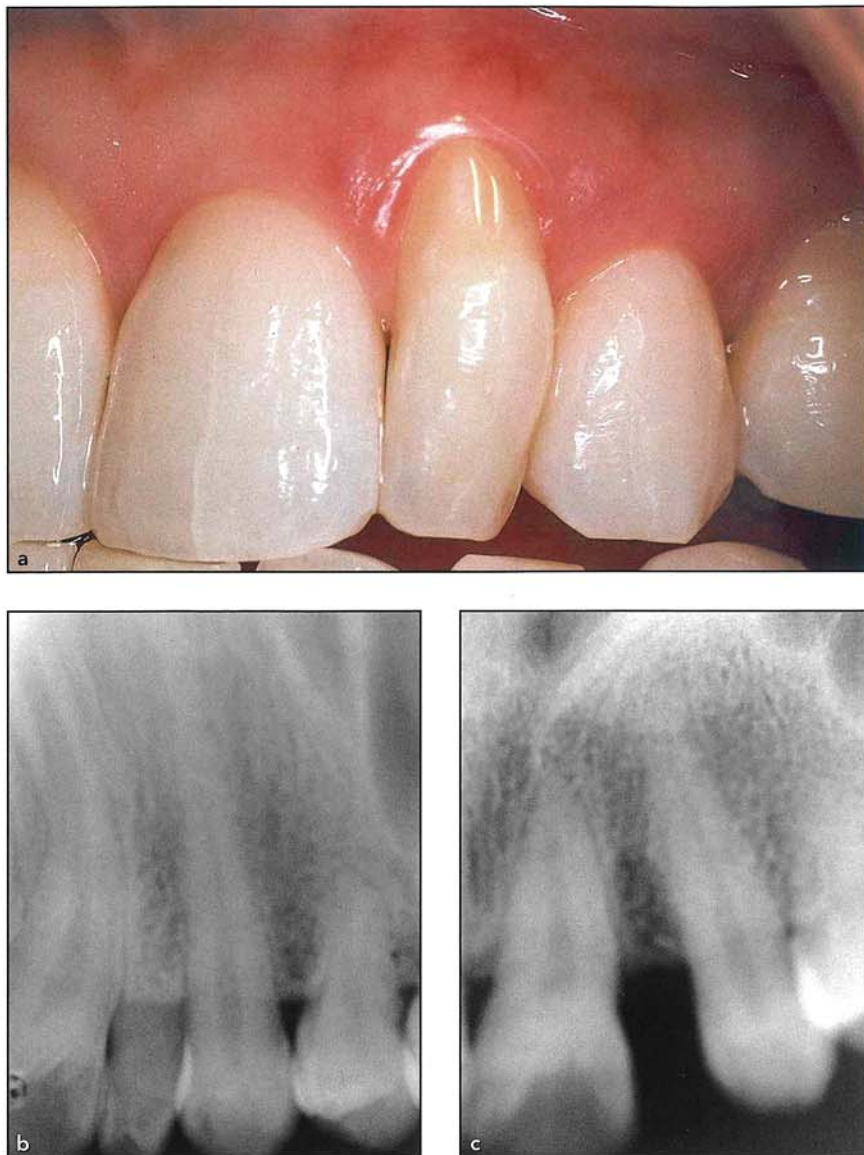<sup>4</sup>Ashman Department of Periodontology and Implant Dentistry, New York University College of Dentistry, New York, New York, USA.

Correspondence to: Dr Stuart J. Froum, 17 W. 54th Street, Suite 1C/D, New York, NY 10019, USA. Fax: 212-246-7599.  
 Email: dr.froum@verizon.net

Submitted July 17, 2019; accepted September 3, 2019.  
 ©2020 by Quintessence Publishing Co Inc.







**Figs 1a to 1c** (a) A 36-year-old woman presented with a retained deciduous maxillary left lateral incisor. Preoperative radiographs showing the deciduous tooth (b) before and (c) after extraction.

types of cardiovascular disease requiring they take anticoagulants. The less-invasive drilling protocol, flap reflection, and avoidance of the need for augmentation procedures with NDIs results in less bleeding and can oftentimes be completed without stopping consumption of anticoagulants. These limitations decrease the capability of SDIs to be a

universal implant treatment option. A thorough assessment of these variables is paramount in treatment planning for implant placement to decrease the risks of implant failure or complications.

In cases where SDIs with diameters between 2.9 mm and 4.3 mm are unable to be used, mini implants and NDIs with diameters

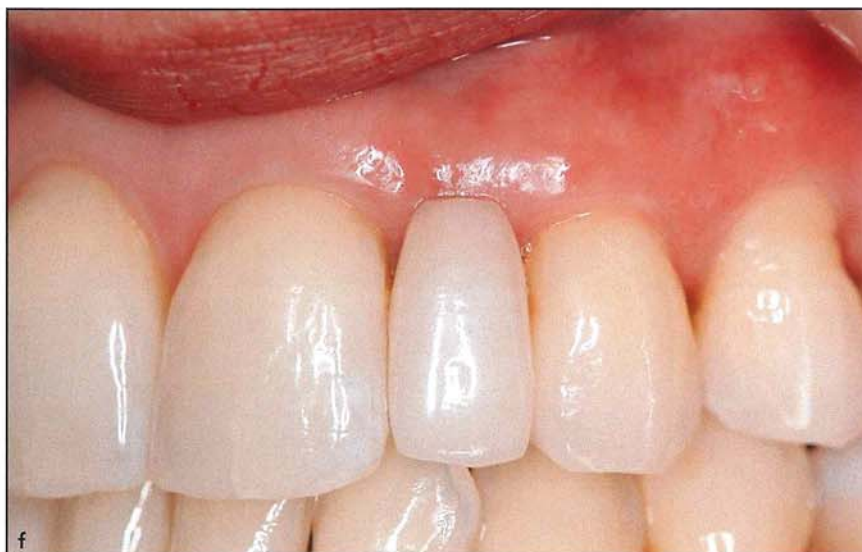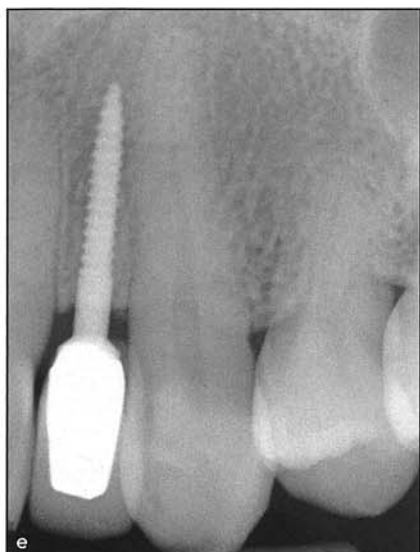
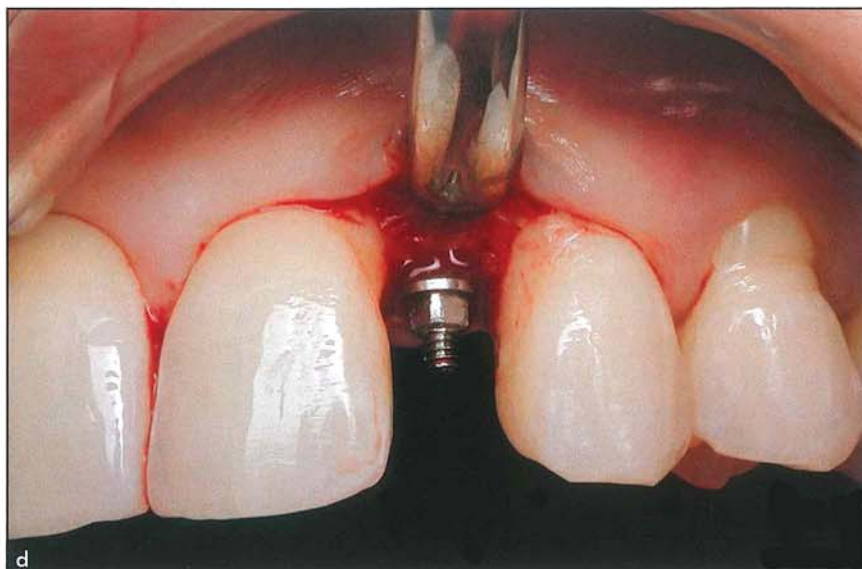
of less than 2.9 mm may be an option.<sup>7</sup> Mini implants and NDIs have been categorized by diameter, starting from Category 1 mini implants (< 3.0 mm) and including Category 2 (3.00 to 3.25 mm) and Category 3 (3.30 to 3.50 mm).<sup>8</sup> A recent case series presented five case reports using mini dental implants in areas of deficient ridge width or interdental space.<sup>9</sup> However, permanent indications of NDIs include not only replacement of missing lateral maxillary or mandibular incisors but also retention of overdentures, full-arch immediate loading, and implant-supported restorations in areas where mesiodistal distance limits the use of SDIs or even implants with 2.9- to 3.3-mm diameters (Table 1).<sup>10-21</sup> Despite the various clinical advantages that NDIs present for specific conditions, there has been limited discussion in the literature of these expanded uses of NDIs.

The purpose of this report is to present various expanded, permanent uses of NDIs, their indications, and their limitations, and to discuss the advantages and disadvantages of using NDIs for permanent restorations.

## Materials and Methods

The NDIs discussed in this report are all Category 1 (1.8-, 2.2-, and 2.4-mm diameters) and come from the same manufacturer (Anew, Dentatus). All implants are one piece with a combined roughened surface and 4-mm machined coronal aspect. They are self-tapping and are placed with a

**Figs 1d to 1f** (d) Intraoperative facial view showing a reduced interdental span and the NDI ( $2.2 \times 14$  mm) in place. (e) Radiographic and (f) clinical views 19 years later, showing the implant in place and restored with a screw-retained porcelain-fused-to-metal crown.



1.4-mm drill into dense type 1 bone, followed by either the 1.8-mm or 2.0-mm-diameter drill depending on the selected implant diameter. A round bur is used to widen the crestal osteotomy to accommodate the machined collar. After implant placement, a resin cylinder is placed over the platform and secured with a screw-retained cap. The provisional is fabricated with a 3-mm hole

drilled in the cingulum area to screw the restoration to the implant. Care must be taken to place the implant in the ideal restorative position, using a surgical guide made from an ideal wax-up, so it emerges in the cingulum area of the placed restoration. The implant should be a minimum distance of 1.2 mm from the adjacent teeth. When placed in an anterior area, the cone beam

computed tomography (CBCT) scan simulation will help determine whether proper implant placement will require simultaneous buccal or lingual augmentation using guided bone augmentation in areas with < 2 mm buccal or lingual bone. The provisional should be adjusted to be out of occlusion in centric and excursions. Postsurgical instructions should be given, stressing that the



**Table 1 Permanent Uses for Narrow-Diameter Implants**

Applications	Indications	Limitations
Congenitally missing maxillary lateral incisor	For a fixed single-tooth restoration in a site with limited mesiodistal space	Decreased strength; may require addition of a graft to enhance esthetics
Missing maxillary incisor	For a fixed single-tooth restoration in a site with limited mesiodistal space	Decreased strength; may require addition of a graft to enhance esthetics
Mandibular incisors	Mesiodistal limited space	May require buccolingual augmentation of bone
Overdenture	For implant support in knife-edged atrophic alveolar ridges to avoid ridge augmentation procedures	May require buccolingual augmentation of bone if standard-diameter implants are required

patient should not bite on the provisional for at least 12 weeks. If the patient is a bruxer, clencher, or hard biter, an occlusal guard should be made and worn at night. The screw-retained final crown allows easy access if the crown requires replacement due to fracture, wear, or requiring a change of shade. It is recommended that these implants be splinted to additional NDIs or to SDIs to accommodate for additional occlusal load if they are used in the posterior areas.

### Permanent Uses of NDIs

#### *Congenitally Missing or Extracted Maxillary Lateral Incisors*

Two studies reported the prevalence of congenitally missing lateral incisors as 1.91% and 2.2% in two different ethnic populations.<sup>22,23</sup> In fact, the overall presence of hypodontia of maxillary lateral incisors falls within the reported range of 0.79% to 2.6% of other studies.<sup>22</sup> When restoring a congenitally missing or extracted maxillary lateral incisor, the limited mesiodistal space is often a contra-

indication for the placement of an SDI that requires a minimum mesiodistal space of 6.0 to 6.5 mm for successful permanent osseointegration. Placement of an NDI can be a successful alternative in these cases, which allows osseointegration and is an esthetic solution for the patient, without the reduction of adjacent teeth, orthodontic movement, or the inconvenience of a removable prosthesis (Fig 1). In a retrospective study, Froum et al examined 19 NDIs placed in 14 patients with congenitally missing lateral incisors and reported a survival rate as well as a patient satisfaction rate of 100%. These results are consistent with the survival rates of SDIs (Fig 2).<sup>24</sup>

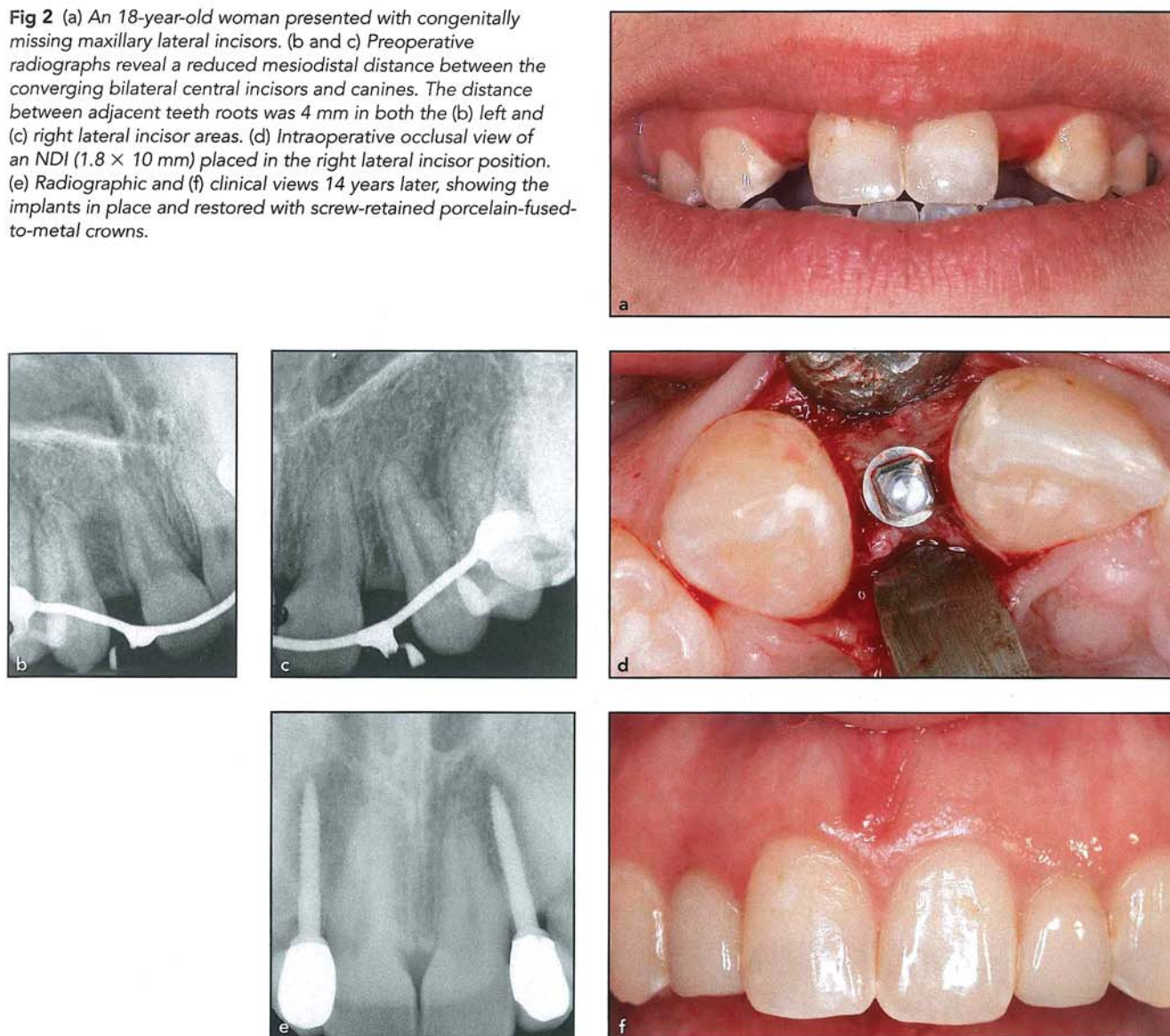
#### *Mandibular Anterior Incisor Region*

Although there are no reports on the prevalence of missing mandibular incisors, this condition was found to be more common in Japanese, Chinese, and Korean populations. Moreover, the congenital absence of lower incisors can result in minimal volume of bone for the placement of endosseous implants in

locations favorable for subsequent restorations.<sup>25</sup> The mandibular anterior region is often a challenge to restore when teeth are missing due to its limited mesiodistal and/or buccolingual space. The alveolar ridge may not have enough bone quantity, quality, or space for an SDI. Moreover, a tooth-supported removable prosthesis requires the reduction of sound tooth structure and may expedite the rate of bone resorption. In these cases, NDIs can be placed and result in improved function and esthetics. The NDI-supported prosthesis does not require any tooth reduction for abutment teeth. When the NDI is placed > 1.0 mm from the adjacent teeth in mandibular anterior regions, it can significantly reduce the rate of bone resorption (Fig 3). Froum et al<sup>24</sup> reported on the success of NDI placement in narrow mandibular anterior regions in a case series in which 10 of 14 subjects each received an NDI in the mandibular incisor areas and were followed for 3 to 14 years. All implants were successful and none showed no surgical or prosthetic complications. The NDIs used in these cases usually required diameters of 1.8, 2.2, and 2.4 mm (Anew, Dentatus).



**Fig 2** (a) An 18-year-old woman presented with congenitally missing maxillary lateral incisors. (b and c) Preoperative radiographs reveal a reduced mesiodistal distance between the converging bilateral central incisors and canines. The distance between adjacent teeth roots was 4 mm in both the (b) left and (c) right lateral incisor areas. (d) Intraoperative occlusal view of an NDI ( $1.8 \times 10$  mm) placed in the right lateral incisor position. (e) Radiographic and (f) clinical views 14 years later, showing the implants in place and restored with screw-retained porcelain-fused-to-metal crowns.



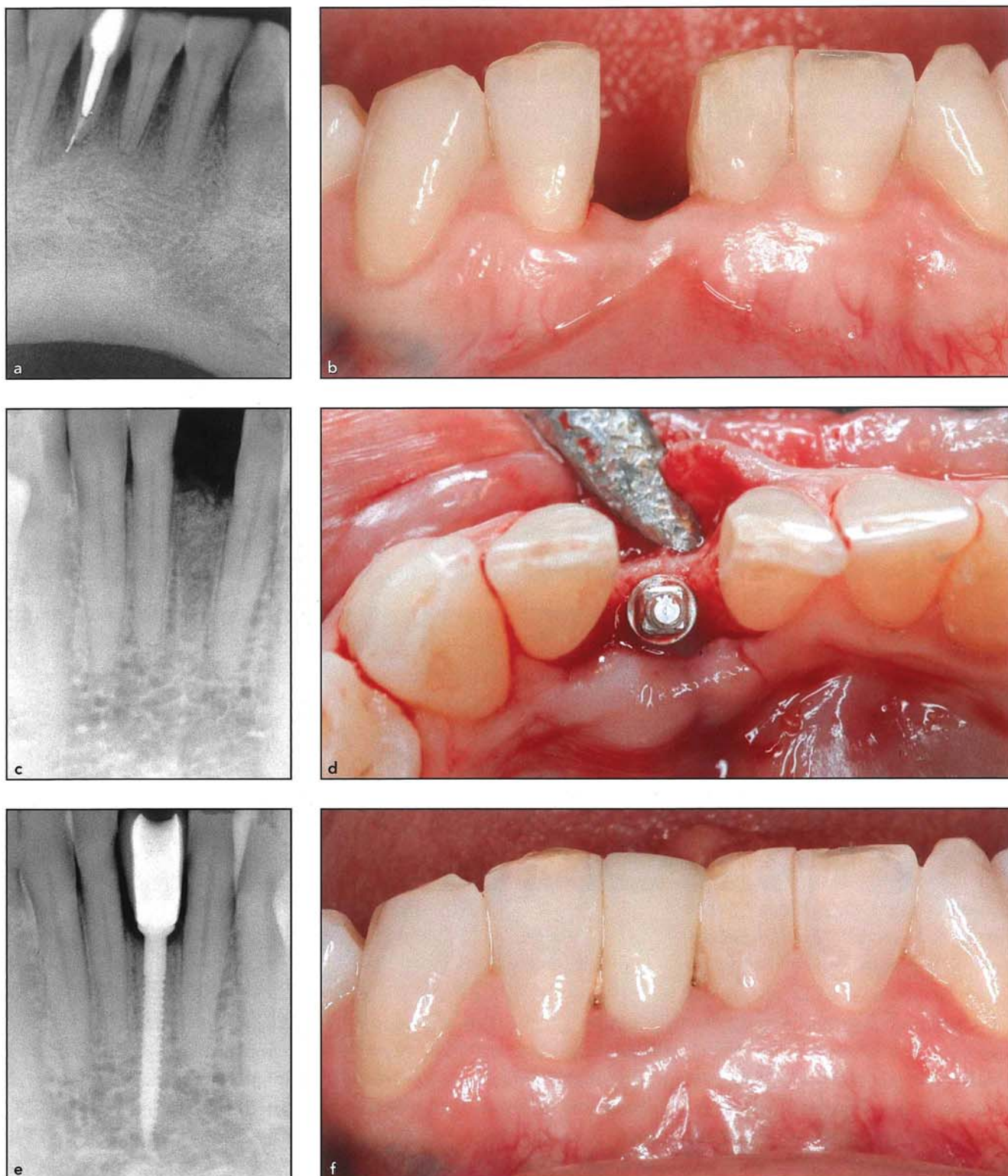
### Overdentures

The American Academy of Prosthodontics reported that 23 million Americans were completely edentulous and 12 million Americans were edentulous in one arch.<sup>26</sup> While implant-retained overdentures are often an excellent treatment option with a high success rate, there are

limitations on the size and length of implants that can be placed when the edentulous mandible is severely resorbed. Oftentimes, atrophic mandibular ridges require extensive ridge augmentation in order to increase the buccolingual space for SDIs. However, the placement of two to four NDIs can serve as a better option to support an

overdenture (Fig 4). In an atrophic mandibular ridge without extensive augmentation procedures, Cho et al reported that the placement of NDIs instead of SDIs can reduce both the cost and medical complications for the patient while maintaining the high success rate and patient satisfaction of a standard overdenture.<sup>21</sup> This longitudinal study of 14 to 36

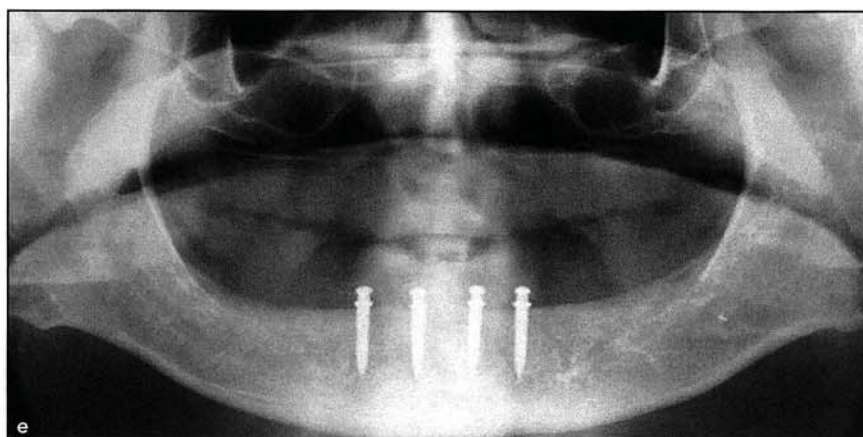
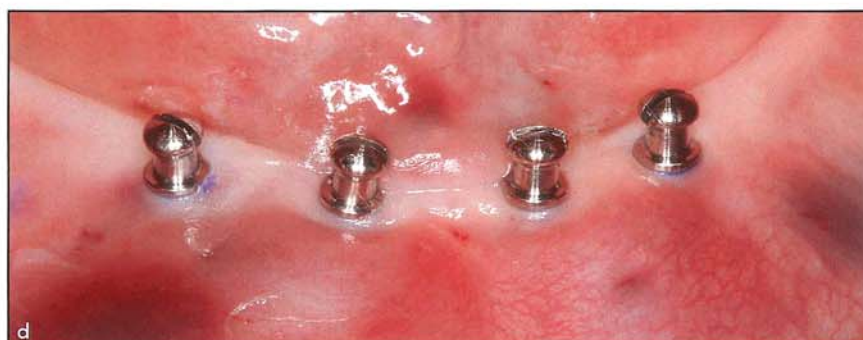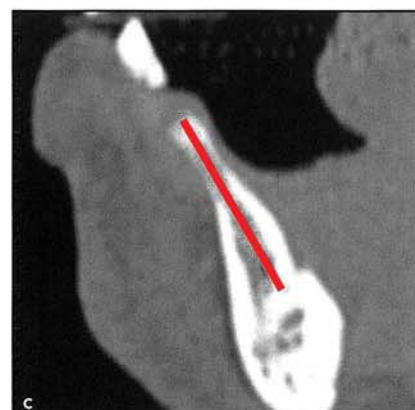
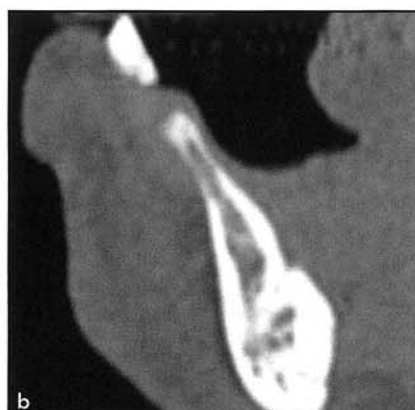

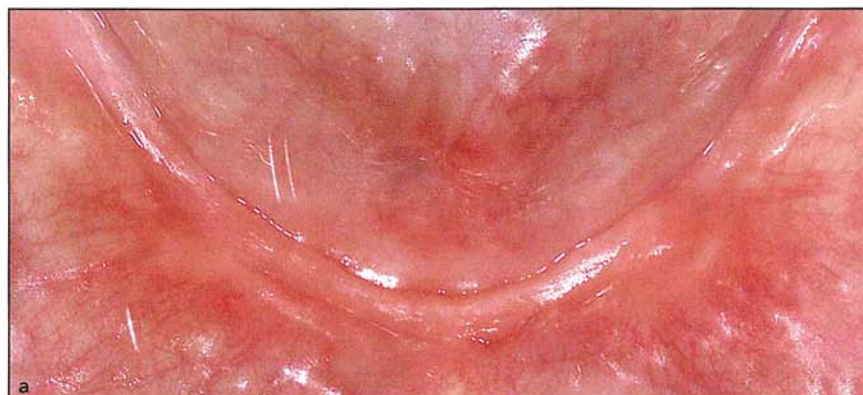


**Fig 3** (a) A 53-year-old woman presented with a hopeless, mobile mandibular right central incisor, which was later extracted. (b) Preoperative clinical and (c) radiographic views 6 months later revealed a reduced mesiodistal distance between the left central incisor and right lateral incisor (measures 4.4 mm at the apices of the adjacent teeth). (d) Intraoperative occlusal view of the NDI (2.2 × 14 mm) placement in the mandibular right central incisor position. (e) Radiographic and (f) clinical views 9 years later, showing the implant in place, restored with a screw-retained porcelain-fused-to-metal crown.



**Fig 4** (a) The patient presented with an atrophic edentulous mandible and a poorly retained mandibular complete denture. (b and c) A preoperative CBCT scan reveals a severely atrophic edentulous mandible with too limited a buccolingual space to accommodate SDIs. The red line indicates the direction of the implant relative to the surgical guide, as determined by CBCT scan and Simplant software. (d) Intraoperative facial view of four NDIs ( $2.2 \times 14$  mm) following flapless placement in the edentulous mandible. (e) A panoramic radiograph taken at the 6-year follow-up of the NDIs in situ supporting an overdenture.



months showed a success rate of 94.1% for immediately loaded NDIs for overdentures. A recent systematic review on the survival of mini dental implants (NDIs) retaining mandibular complete overdentures concluded that these implants have excellent survival rates in the short to medium term and should be considered "a reasonable alternative treatment modality to retain mandibular complete overdentures."<sup>22</sup>

## Results

Ninety-six NDIs (1.8 to 2.4 mm) have been followed for 6 to 19 years in 84 patients with no implant loss or complication other than changing the shade of 8 restorations due to patient aging.



## Discussion

For the most part, general use of NDIs has been limited to the mandibular anterior region of the mouth. However, recent studies have suggested a broader range of NDI applications.<sup>8,12</sup> This review presented the various indications of Category 1 (< 3.0-mm diameter) NDIs for permanent use. Each case should be carefully assessed before treatment to ensure the proper indication for using NDIs. Parameters that should be considered prior to treatment include the size and length of the implant, region of the mouth, anticipated occlusal load, bone quality and quantity, proximity of implant site to adjacent teeth or implant, vital structures, and the patient's history and needs. The use of CBCT scans to allow more thorough diagnostic planning is essential when using NDIs for the purposes discussed in this review. These extended clinical applications of NDIs allow for a broader range of treatment options for differing case scenarios. To fully understand the scope of the Category 1 NDI's capability, permanent uses were explored.

Guidelines for use of mini dental implants have recently been published.<sup>9</sup> However, the implants used in the present retrospective report differ from the ones used in the former report of five case series and have a longer-term follow-up with significantly more implants.

The use of NDIs for support of permanent restorations is less known and should be considered during treatment planning. Permanent NDIs have become a

recognized option for cases where implants are required to be placed in a specific location, as in cases of congenitally missing maxillary lateral incisors or in the mandibular incisor region. The approach of using an SDI conflicts with the limited mesiodistal buccal lingual space, leaving the treatment plan with no other choice than reduction of the tooth structure for fixed restorations or removable prostheses. NDIs offer a solution requiring less mesiodistal space for osseointegration, no bone resorption, and are reported to have similar survival rates as SDIs.<sup>8</sup> Moreover, in areas of deficient alveolar bone requiring augmentation procedures, NDIs can be placed (and splinted, if necessary) to avoid the additional cost, pain, and morbidity of these procedures. This allows an implant option for patients who, due to medical or financial reasons, would otherwise not be candidates for augmentation procedures to place SDIs.<sup>9</sup> In addition, with CBCT scans and guides currently available, many of the NDIs can be placed flaplessly, thus reducing time of surgery, cost, and pain.<sup>7-9</sup> Conventional solutions for limited mesiodistal or buccolingual space and patients with resorbed ridges required bone augmentation, orthodontic tooth movement, or tooth reduction. NDIs offer an alternative option because they require less mesiodistal space and buccolingual bone volume for successful implantation and osseointegration, have a reduced cost, and may be used in medically compromised patients due to their less-invasive placement protocol.

## Conclusions

This report presented various options for permanent use of NDIs. The significant advantages of NDIs range from reduced bone resorption and immediate loading capabilities to cases of the implant lateral to the inferior alveolar nerve and limited mesiodistal space. Selection of the most ideal NDI diameter (1.8, 2.2, or 2.4 mm) should be made on a case-by-case basis. However, this review indicates the broad range and relevant need for NDIs when utilizing implant therapy for restoring edentulous areas of the maxilla and mandible.

## Acknowledgments

The authors declare no conflicts of interest.

## References

1. Mericske-Stern RD, Taylor TD, Belser U. Management of the edentulous patient. *Clin Oral Implants Res* 2000;11(suppl 1):s108-s125.
2. Jimbo R, Albrektsson T. Long-term clinical success of minimally and moderately rough oral implants: A review of 71 studies with 5 years or more of follow-up. *Implant Dent* 2015;24:62-69.
3. Viscioni A, Franco M, Rigo L, Guidi R, Spinelli G, Carinci F. Retrospective study of standard-diameter implants inserted into allografts. *J Oral Maxillofac Surg* 2009;67:387-393.
4. Henry PJ, Laney WR, Jemt T, et al. Osseointegrated implants for single-tooth replacement: A prospective 5-year multicenter study. *Int J Oral Maxillofac Implants* 1996;11:450-455.
5. Buser D, Martin W, Belser UC. Optimizing esthetics for implant restorations in the anterior maxilla: Anatomic and surgical considerations. *Int J Oral Maxillofac Implants* 2004;199(suppl):s43-s61.

6. Sato Y, Shindoi N, Hosokawa R, Tsuga K, Akagawa Y. A biomechanical effect of wide implant placement and offset placement of three implants in the posterior partially edentulous region. *J Oral Rehabil* 2000;27:15–21.
7. Froum SJ, Cho SC, Florio S, Misch CM. Use of narrow-diameter implants in treatment of severely atrophic maxillary anterior region with implant-supported fixed restorations. *Compend Contin Educ Dent* 2016;37:334–339.
8. Klein MO, Schiegnitz E, Al-Nawas B. Systematic review on success of narrow-diameter dental implants. *Int J Oral Maxillofac Implants* 2014;29(suppl): s43–s54.
9. Choi R. A rationale for fixed restorations supported by mini dental implants: Case reports and practical case selection guidelines. *Compend Contin Educ Dent* 2019;40:238–245.
10. Misch K, Neiva R. Small-diameter implants for optimal stabilization of implant-supported overdentures. *Pract Proced Aesthet Dent* 2007;19:428–431.
11. Bichacho N, Landsberg CJ, Rohrer M, Davidovich Y. Immediate fixed transitional restoration in implant therapy. *Pract Periodontics Aesthet Dent* 1999; 11:45–51.
12. Froum S, Emtiaz S, Bloom MJ, Scolnick J, Tarnow DP. The use of transitional implants for immediate fixed temporary prostheses in cases of implant restorations. *Pract Periodontics Aesthet Dent* 1998;10:737–746.
13. Gallucci GO, Finelle G, Papadimitriou DE, Lee SJ. Innovative approach to computer-guided surgery and fixed provisionalization assisted by screw-retained transitional implants. *Int J Oral Maxillofac Implants* 2015;30:403–410.
14. Simon H. Use of transitional implants to support a surgical guide: Enhancing the accuracy of implant placement. *J Prosthet Dent* 2002;87:229–232.
15. Oleaga M, Elzer A, Yu CH, Yip J, Cho SC, Froum S, Bloom M. Utilizing Anew narrow diameter implants as a tent pole for vertical ridge augmentation—Case studies [poster]. New York University; Academy of Osseointegration. 2012.
16. Keller W. Temporarily replacing congenitally missing maxillary lateral incisors in teenagers using transitional implants. *Implant News and Views* 2001;3:1,4,5,10.
17. Kang HW, Zangrandi D, Hong WT, et al. The use of computerized tomographic scans to guide implant placement lateral to the inferior alveolar canal [poster]. New York University; Academy of Osseointegration 2012.
18. Park J, Fatakhov R, Kim E, et al. Clinical application of mini implants for minor tooth movement and provisional restoration [poster]. New York University; Academy of Osseointegration 2009.
19. Gray JB, Smith R. Transitional implants for orthodontic anchorage. *J Clin Orthod* 2000;34:659–666.
20. Cope JB, McFadden D. Temporary replacement of missing maxillary lateral incisors with orthodontic mini screw implants in growing patients: Rationale, clinical technique, and long-term results. *J Orthod* 2014;41(suppl 1):s162–s174.
21. Cho SC, Froum S, Tai CH, Cho YS, Elian N, Tarnow DP. Immediate loading of narrow-diameter implants with overdentures in severely atrophic mandibles. *Pract Proced Aesthet Dent* 2007;19:167–174.
22. Jawad S, Clarke PT. Survival of mini dental implants used to retain mandibular complete overdentures: Systematic review. *J Oral Maxillofac Implants* 2019;34:343–356.
23. Bäckman B, Wahlin YB. Variations in number and morphology of permanent teeth in 7-year-old Swedish children. *Int J Paediatr Dent* 2001;11:11–17.
24. Froum SJ, Shi Y, Fisselier F, Cho SC. Long-term retrospective evaluation of success of narrow-diameter implants in esthetic areas: A consecutive case series with 3 to 14 years follow-up. *Int J Periodontics Restorative Dent* 2017;37: 629–637.
25. Nagaveni NB, Umashankara KV. Congenital bilateral agenesis of permanent mandibular incisors: Case reports and literature review. *Arch Orofac Sci* 2009;4:41–46.
26. Dye BA, Thornton-Evans G, Li X, Iafolla TJ. Dental caries and tooth loss in adults in the United States, 2011–2012. *NCHS Data Brief* 2015;(197):1–8.