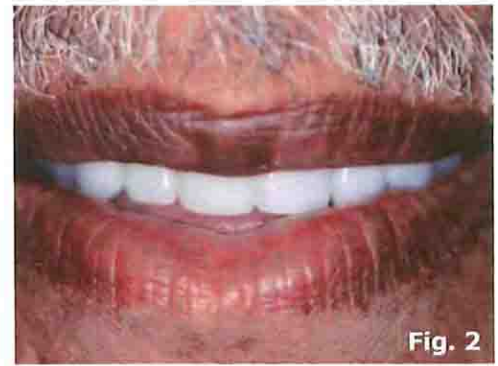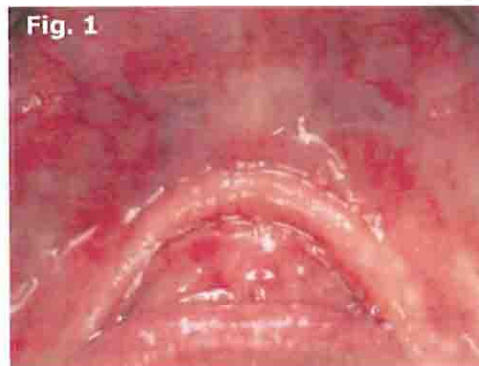


## Case Presentation: Overdenture Alternative with Narrow Body Implants

by Dr. Timothy Kosinski and Dr. Robert Kline

A 69 year-old black male presented to our office who had undergone bilateral osteotomies of the mandible. Following the surgical procedure, the patient had great difficulty tolerating his conventional mandibular complete denture. His quality of life was dramatically decreased due to the instability of the appliance. The patient's health history was relatively unremarkable except for treatment for high blood pressure.

The patient came to my office for consultation about "mini-implants." It was determined through oral and radiographic examination that the small diameter implants could be placed in the symphysis area without complication [fig 1]. Cost was a big factor in determining the type of implants to be placed since the patient just had his new conventional, mandibular denture fabricated [figs. 2-3].



### Narrow Body Implants

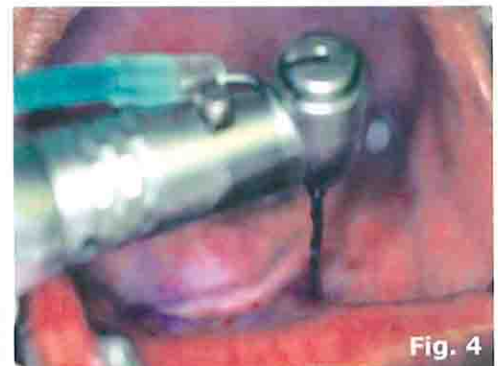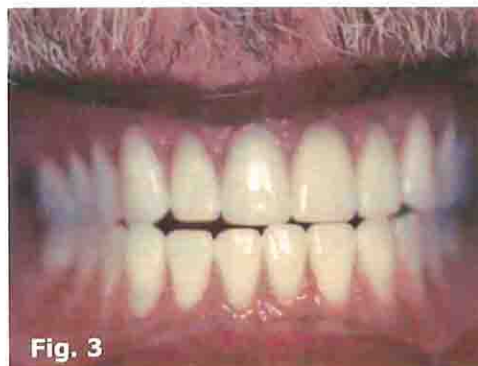Four 2.2 mm X 10 mm Atlas dental implants (Dentatus USA, NY, NY) were strategically surgically placed without complication [figs. 4-8]. This was a flapless procedure which the patient tolerated exceptionally well under local anesthetic only. His existing complete denture was reamed out and relined with Tuf-Link Resilient Silicone Material (Dentatus USA, NY, NY) [fig. 9].

No o-rings or copings are required with this system, so the prosthetic portion went smoothly. The patient had immediate stabilization of his mandibular denture, and the stability allowed him to function with maximum intercuspation of his denture teeth. The patient was thrilled with the result and amazed that his denture had such good immediate retention [fig. 10].

This patient had worn conventional dentures for the past 42 years, but now has an appliance that gives him comfort, stability and increased chewing ability.

### Fees

The patient was charged \$2,100 for the 4 im-



plants at \$525.00 each and \$625 for the reline material, for a total of \$2725. The procedure took about an hour of chair time.

### Options

The patient was unable to tolerate his conventional mandibular denture. We could have placed two traditional dental implants in the symphysis and fabricated an implant-retained overdenture with attachments such as Locator Attachments.

The normal fee for this procedure would be approximately \$7300. Therefore, the fee for the narrow body implant case using the existing denture vs traditional implants and a new overdenture is nearly 63% less, and the patient has a denture they can function on immediately. This is a great service to a group of patients who may not otherwise experience the benefits of implant dentistry.

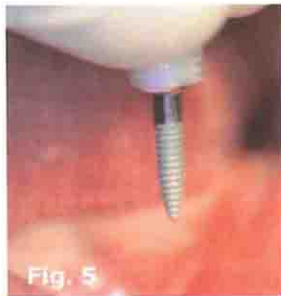


Fig. 5

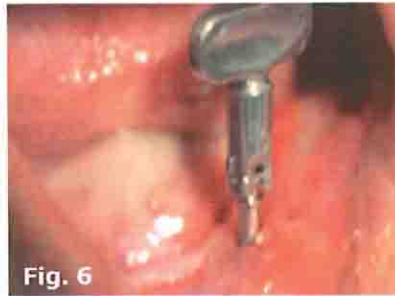

Fig. 6

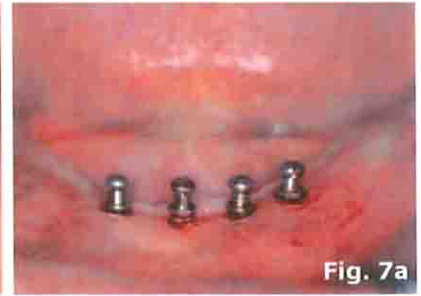

Fig. 7a

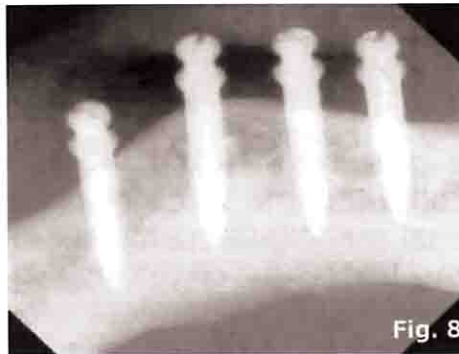


Fig. 8

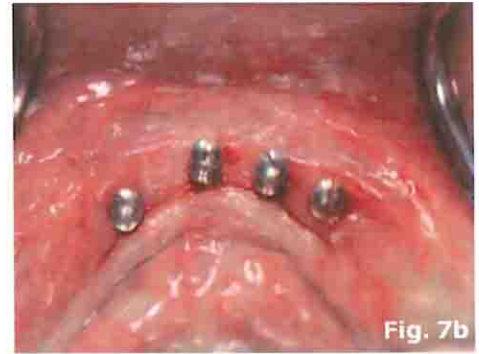


Fig. 7b

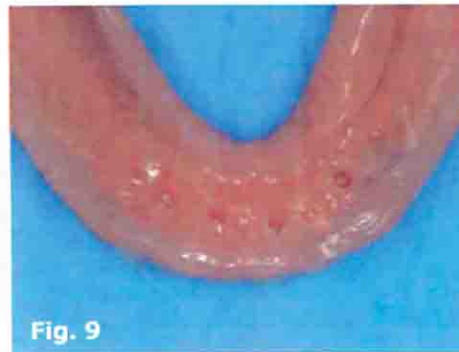

Fig. 9

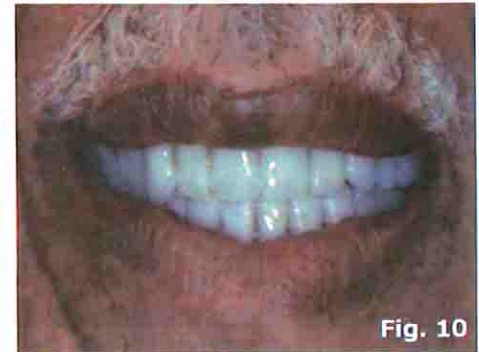

Fig. 10

Compliments of

Dentatus USA, Ltd.  
192 Lexington Ave.  
New York, NY 10016  
Tel.: 800-323-3136  
dentatus@dentatus.com



Dentatus AB  
Jakobsdalsvägen 14-16  
S-126 53 Hägersten, SWEDEN  
Tel.: +46 8 546 509 00  
info@dentatus.se

www.dentatus.com