

Functional Esthetics & Restorative Dentistry

A COMPREHENSIVE RESOURCE FOR ADVANCED LEARNING

SERIES 1

Dental Implants

CASE REPORTS:

*Robert A. Levine, DDS, and
Robert A. Horowitz, DDS*

Robert A. Jaffin, DMD

Robert A. Levine, DDS

Frank M. Spear, DDS, MSD

Paul Petrungaro, DDS, MS

Treatment Planning:

Shadi Daher, DMD, FAAOMS

Team Building:

Keith D. Rossein, DDS

Practice Marketing:

*Ron Geraneo, BS, and
Robert A. Horowitz, DDS*

Essentials:

*Overdenture Considerations
Robert C. Vogel, DDS*

Loading Protocols

Frederic J. Norkin, DMD;

Jeffrey Ganeles, DMD;

Julio Sekler, DMD, MMSc;

Samuel Zfaz, DDS

Dental Implant Abutment Selection

Lyndon F. Cooper, DDS, PhD;

Ingeborg J. De Kok, DDS, MS;

Lee Culp, CDT

Current Implant Designs

Robert A. Horowitz, DDS

Management of the Compromised Intertooth Space with Small-Diameter One-Piece Implants in the Esthetic Zone

PAUL PETRUNGARO, DDS, MS

ABSTRACT: *The use of dental implants to replace the natural tooth system has become commonplace in the contemporary dental practice, but some impediments to their use have traditionally included the smaller edentulous intertooth spaces, reduced vertical or transverse dimension of the residual ridge, convergent roots, and/or close proximity of root trunks. However, the advent of smaller diameter implants and their documented use in the literature over the past 15 years lends to their acceptable placement for treatments ranging from immediate stabilization of bone augmented ridges to esthetic tooth replacement in the esthetic zone. This article presents two case reports to demonstrate the minimally invasive surgical placement of narrow-diameter implants for the treatment of congenitally missing lateral incisors in an esthetic manner.*

The use of dental implants to replace the natural tooth system has become commonplace in the contemporary restorative and surgical dental practice.^{1,2} Substantiation of their efficacy has been well-documented in restorative, cosmetic, and surgical dental literature,^{1,2} and with the advancements in surgical techniques and implant design features, their use in the esthetic zone has become a successful and predictable tooth replacement option.³⁻⁷

However, some impediments to the use of dental implants remain.⁹⁻¹² Smaller edentulous intertooth spaces, reduced vertical or transverse dimension of the residual ridge, convergent roots, and/or close proximity of root trunks can cause the implant team to opt for other options to replace the natural tooth system, usually a resin-bonded fixed prosthesis or a removable prosthesis. Another common deterrent to the use of dental implants is the compromised edentulous space remaining in the congenitally missing lateral incisor area of the maxillary anterior, either pre- or postorthodontic

treatment. Often times cases of this type result in tooth replacement options of a removable type or some type of resin-bonded bridge, as previously mentioned. Extreme treatment of these spaces can also end in a full-coverage restoration on the abutment teeth, with a fixed pontic to replace the edentulous space. In younger individuals, this can result in significant destruction to the natural teeth adjacent to the edentulous site, the possibility of future endodontic treatment, and premature tooth loss. Additionally, a compromised esthetic result is usually obtained due to the insufficient tooth-to-tooth space.¹¹⁻¹³

To properly form an ovate pontic emergence profile in the soft tissue, which is necessary to provide for a natural appearance of the pontic in the fixed bridge tooth replacement option, certain considerations must be discussed when replacing the congenitally missing or compromised intertooth edentulous space. Criteria of the routine

TABLE 1. CLINICAL APPLICATIONS OF NARROW-DIAMETER, ONE-PIECE IMPLANTS RANGING IN DIAMETER (1.8 MM TO 3.0 MM)

- Immediate loading of a provisional appliance
- Orthodontic anchorage
- Immediate full-arch edentulous denture stabilization
- Single-tooth replacement, compromised intertooth space
- Cases requiring minimally invasive surgical procedures. (ie, health concerns, residual ridge deficiencies, advanced oral infections)
- Management of congenitally missing natural teeth
- Management of mandibular central and lateral incisions



PAUL PETRUNGARO, DDS, MS, FICD, FACD, DICOI, is the founder and director of the Institute for Advanced Dental Education, Inc., located in Lake Elmo, MN. He maintains private practices focusing on cosmetic periodontology and implantology in Chicago, IL, Lake Elmo, MN, and Sao Paulo, Brazil. He may be reached at kara@petrungaro.com.

implant site require that a normal two-piece implant be placed at least 1.5 mm from the adjacent teeth.¹²⁻¹³ As such, the width of an edentulous space that will receive this type of dental implant should be at least 6.5 mm wide, taking into consideration 1.5 mm from the adjacent teeth and the implant diameter being 3.5 mm; 7.5 mm if the implant diameter is 4.5 mm; and 8.5 mm if the implant diameter is 5.5 mm. The implant team must also consider that the width of the abutment is usually greater than that of the implant itself, which leads to the proper emergence profile formation of the soft tissues supporting the planned final restoration. Therefore, the minimum intertooth space must be raised by at least 1 mm to accommodate the final restoration.

Taking these parameters into account, larger diameter implants cannot be used to treat these compromised sites. This has led to the development and utilization of narrower diameter implants, which has been documented in the dental literature over the last 15 years.¹⁵⁻²² Manufacturers have provided small-diameter implants ranging in diameter from 1.8 mm to 3.3 mm in width, and 8 mm to 16 mm in length. Their use in implant treatment has ranged from immediate stabilization of bone augmented ridges to esthetic tooth replacement in the esthetic zone. Currently there are various uses for narrow-diameter implants (Table 1).

Further expansions of their use also led to design feature changes and, due to compromised intertooth width and resultant emergence profile formation issues, the one-piece implant design has become more accepted as a tooth replacement option in these types of cases.

Systems that incorporate the abutment as part of the implant itself do not have a gap between the implant body and abutment connection and, therefore, bone loss over time may be reduced with their use.¹¹⁻¹⁴ The reduction in the diameter of the crestal portion of the one-piece design allows for crucial millimeters of space to be conserved in the compromised intertooth space which, when used to replace the natural tooth system in the esthetic zone, can be a critical factor in the esthetic result obtained in the compromised sites.

The following case reports demonstrate two different implant design features utilized to treat compromised intertooth spaces resulting from congenitally missing lateral incisors. Both cases were managed by a minimally invasive surgical placement approach and the immediate provisionalization procedure to aid in the sculpting of the soft tissue emergence profile, which is necessary for the final esthetic restoration.

CASE #1: Replacement of a Congenitally Missing Lateral Incisor, Postorthodontic Treatment, in a 20-year-old Female Patient

A 20-year-old non-smoking female presented for esthetic enhancement of the anterior sextant (Figure 1) and replacement of the right lateral incisor that was congenitally missing (Figure 2). The edentulous space measured 6.0 mm from the mesial of tooth No. 6 to the distal of tooth No. 8, making an implant of 3.0 mm or less necessary to address the constricted edentulous space. The preoperative digital periapical radiograph (Figure 3) demonstrated the compromised edentulous space between the roots of teeth Nos. 6 and 8.

After gathering maxillary and mandibular study models and a facebow transfer, the fabrication of a diagnostic wax-up of the maxillary anterior sextant was accomplished. From this diagnostic wax-up, which outlined the planned facial tissue heights of contour and dimensions for the final restorations, a surgical guide/provisionalization system^a was constructed. This guide was used as the surgical stent and, after the implant

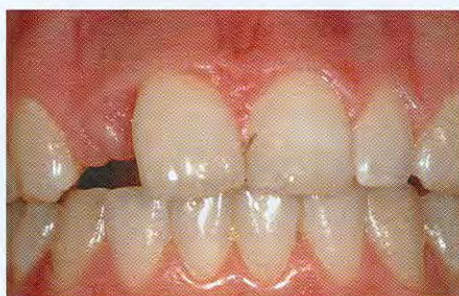

FIGURE 1 Preoperative facial view of a patient with a congenitally missing right lateral incisor.

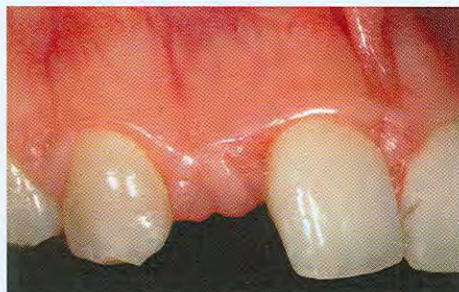

FIGURE 2 Preoperative close-up view of the right lateral incisor space.



FIGURE 3 Preoperative digital periapical radiograph demonstrates limited intertooth space.

^a TempStent II, Contemporary Periodontics & Implantology, Lake Elmo, MN

CASE REPORT

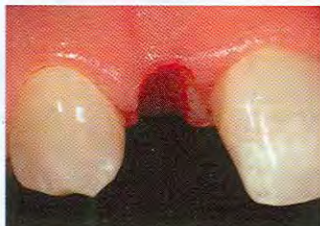

FIGURE 4 The sculpted crestal emergence profile was necessary to achieve balance and symmetry.

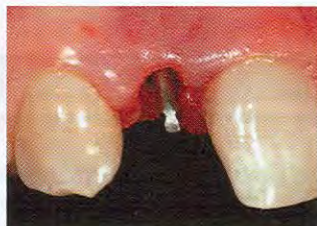

FIGURE 5 View following minimally invasive implant placement. Note the position of the abutment portion in relation to the sculpted emergence profile in the gingival/crestal tissue.

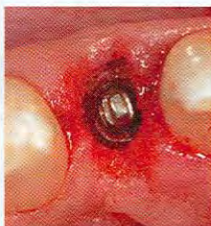

FIGURE 6 Minimally invasive bone grafting was achieved by making a pouch at the buccal aspect of the site.

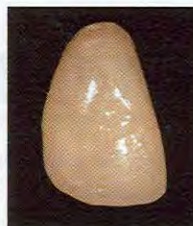

FIGURE 7 View of the final provisional restoration.

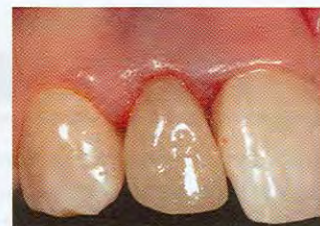

FIGURE 8 Immediate postoperative clinical view of patient with the provisional in place.

was seated, was converted to the provisional restoration seated at the implant placement appointment.

After administration of an appropriate local anesthetic, the surgical guide was placed into the edentulous site and a marking made in the gingival osseous crest with a round #6 bur in the implant handpiece. This registered the planned implant location in the osseous gingival crest. The creation of the esthetic soft tissue emergence profile in the gingival and osseous tissue was then achieved with a football-shaped, medium-coarse diamond (Figure 4). This emergence profile was created to sculpt the interdental soft tissue contours, along with the facial emergence profile necessary to achieve balance and symmetry with the adjacent teeth and the contralateral tooth in the anterior sextant.

Once this was accomplished, the osteotomy site was cored to 2.3 mm in diameter by 11.5 mm in length, followed by increasing the diameter of the site to 2.8 mm with the subsequent spade drill. A 3.0 mm in diameter by 11.5 mm in length one-piece implant^b was then seated into the osteotomy site using more instrumentation. Care was given to placement parameters, since for every full rotation of the implant collar, 1.25 mm of depth of the threads are engaged apically into the osseous crest. This was important because the facial aspect of the collar of the abutment portion of the implant must be to the facial, since it is more crestally placed in relation to the palatal margin of the abutment aspect of the implant. This allowed for a more sculpted

^b Zimmer Dental, Carlsbad, CA

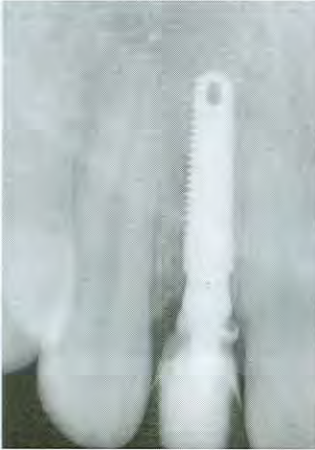

FIGURE 9 Immediate postoperative digital periapical radiograph.

facial emergence profile. The implant and abutment collar were confirmed to be in the appropriate position (Figure 5).

The concavity at the facial aspect of the gingival buccal tissues was addressed with a graft complex of the patient's own Platelet Rich Plasma (PRP) fabricated from a 20 cc blood draw presurgically and an allogenic grafting substrate material,^c 1 mm to 2 mm in particle size. The PRP/grafting complex was inserted into a full-thickness pouch created with an elevator^d (Figure 6).

This pouch was made at the buccal aspect of the osteotomy site and carried 2 mm in each dimension on the lateral and inferior aspect of the defect in the facial/buccal plate. The graft complex was firmly condensed into the pouch and increased the buccal width inferior to the periosteum.

Using the provisional coping in a prosthetic kit,^e the stent^a was then retrofitted to the abutment portion of the implant. Marginal integrity to the abutment was registered in the provisional coping, and the gap that may have existed between the provisional coping and the stent^a was filled with a flowable composite.^f The restoration was shaped and contoured out of the mouth (Figure 7), then checked for occlusion and interproximal contact (ie, normal interproximal contact; free of occlusion in centric, protrusive, and right and left lateral excursion movements). Final polishing of the provisional was then performed, and the provisional restoration was cemented with a strong temporary cement. The realized emergence profile of the provisional restoration was contoured to allow for the migration of the gingival tissue to fill in the embrasure spaces in the postoperative healing and maturation phase (Figure 8).

The space present between the implant and the adjacent roots of the natural teeth was confirmed in an immediate postoperative periapical radiograph (Figure 9). At seven days postoperative (Figure 10), the excellent soft tissue health at the facial gingival tissue in the area of the minimally invasive graft placement could be seen, and the developing interproximal soft tissue contours were present. At three months postoperative (Figure 11), excellent soft tissue contours had been realized facially and interproximally. The patient was released to the esthetic/reconstructive dentist for fabrication of the final implant restorations in the remainder of the anterior sextant (Figures 12 through 14).

CASE #2: Replacement of a Congenitally Missing Lateral Incisor Previously Replaced with a Fixed Bridge in a 31-year-old Patient

A 31-year-old non-smoking female patient presented for esthetic enhancement of the maxillary dentition and replacement of the congenitally missing right lateral incisor (Figure 15). The preoperative digital periapical radiograph (Figure 16) clearly showed the narrow intertooth space. The pretreatment view of the edentulous space (Figure 17) showed the lack of a sculpted emergence profile,

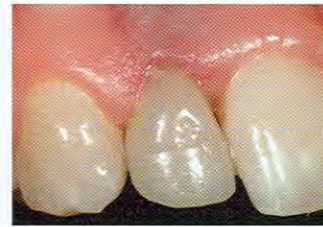

FIGURE 10 View at seven days. Note that the soft tissue contours were developing.

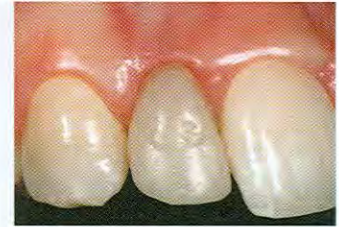

FIGURE 11 At the three-month postoperative appointment, excellent soft tissue contours were realized interproximally.

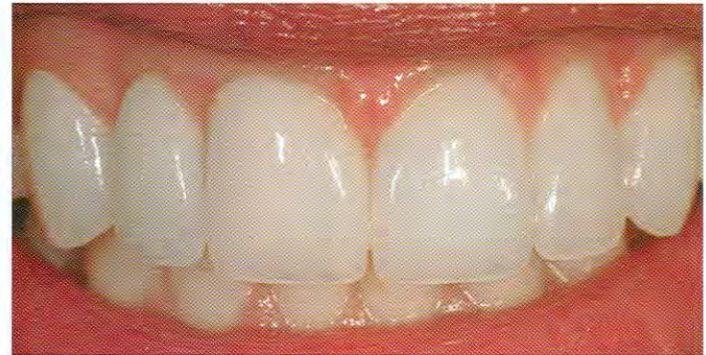

FIGURE 12 Complete facial view of the final case, which includes the final restoration at site No. 7, as well as veneers on teeth Nos. 6 and 8.

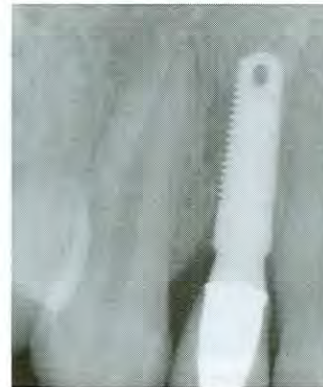

FIGURE 13 View of the digital radiograph of No. 7 upon completion of the case. Note the contoured emergence profile of the osseous crest, which was sculpted at implant placement and is supporting the interdental soft tissue contours.

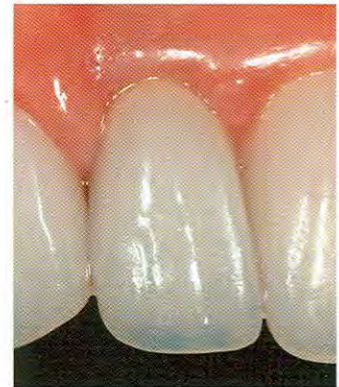

FIGURE 14 Close-up view of the implant-supported restoration.

which prevented balance between the facial height of contour of the edentulous site and that of the left lateral incisor space.

Creation of an ovate pontic type emergence profile was achieved using an oval-shaped diamond bur (Figure 18) that allowed for a sculpted implant receptacle site. Following insertion

^c Puros®, Tutogen Medical, Inc., Alachua, FL

^d Petro-1 Elevator, Salvin® Dental Specialties, Charlotte, NC

^e ZOR Prosthetic Kit, Zimmer Dental, Carlsbad, CA

^f Filtek™ flowable composite, 3M ESPE, St. Paul, MN

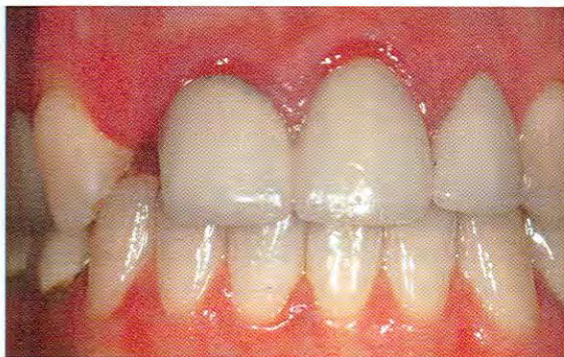

FIGURE 15 Preoperative facial view of a patient presenting with a congenitally missing right lateral incisor.



FIGURE 16 Preoperative digital periapical radiograph showing narrow intertooth space.

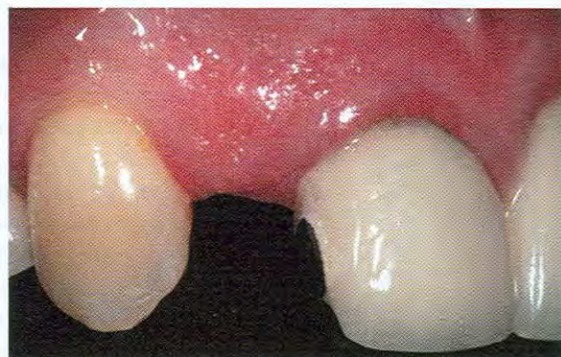

FIGURE 17 Preoperative close-up view of the edentulous space.

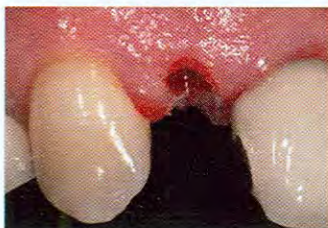

FIGURE 18 An ovate pontic emergence profile was created.

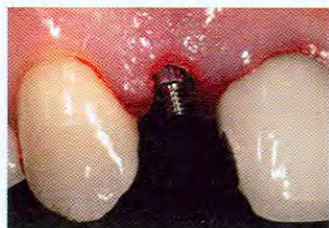

FIGURE 19 Flapless implant placement was accomplished at the No. 7 site.

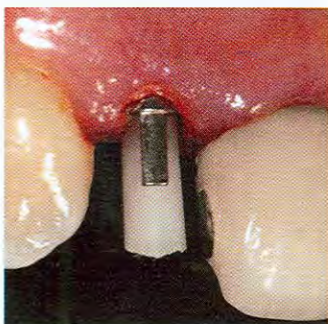


FIGURE 20 A coping center screw assembly was placed and the silicone center shortened.

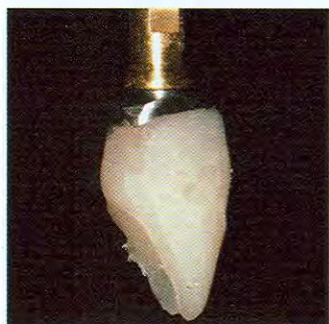

FIGURE 21 Flowable composite was placed around the margins of the coping to correct the marginal integrity.

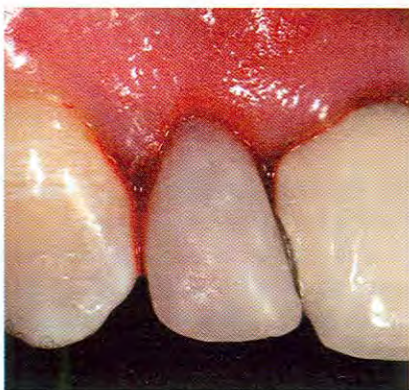

FIGURE 22 Immediate postoperative clinical view with the provisional in place.



FIGURE 23 Immediate postoperative digital periapical radiograph.

of a surgical guide^a, the initial coring was accomplished with the 1.2-mm spade drill using a flapless technique. A 2.2 mm in diameter by 10 mm in length implant was inserted, also using a flapless technique (Figure 19).

Following placement of the coping center screw assembly (Figure 20), the silicone center screw was then shortened, and the surgical guide/provisionalization system^a was retrofitted to the coping/screw assembly. Marginal integrity was obtained out of the mouth by removal of the provisional, placement on an implant analog, and application of flowable composite around the margins of the coping (Figure 21). After final polishing, the provisional was then placed back on the implant fixture and the center screw hand-tightened (Figures 22 and 23).

At two weeks postoperative, it was obvious that excellent soft tissue emergence profile contours were sculpted and maintained from the initial surgical visit through the initial postoperative healing phase (Figure 24). After a three-month healing and maturation period, the patient was then referred back to the restorative clinician for construction of the final restoration and completion of the esthetic enhancement of the maxillary anterior sextant. After preparation of teeth Nos. 6 through 11 for full-coverage restorations, insertion of an impression coping over the implant^b preceded final impression techniques. Laboratory procedures allowed for the fabrication of a pressed ceramic coping (Figure 25) and all-ceramic restoration (Figure 26) to be placed in conjunction with the all-ceramic restorations at teeth Nos. 6 through 11.

Upon completion of the case (Figure 27), a natural appearing soft tissue emergence profile was obtained at the maxillary right lateral implant site, along with the balance and symmetry of the adjacent restorations (Figure 28).

CONCLUSION

The management of compromised intertooth spaces presents a challenge for the contemporary dental implant team. Often times the edentulous space is less than 5 mm from tooth to tooth. These spaces present limits on how they are handled and require implants 3.0 mm wide or less, as demonstrated in this article. Availability of smaller diameter implants provides patients that normally would have to proceed with a fixed or resin-bonded bridge with the luxury

^a ANEW™, Dentatus® USA, New York, NY

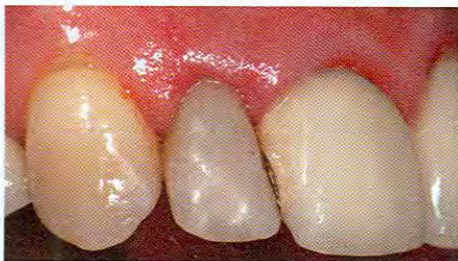

FIGURE 24 At two weeks postoperative, excellent soft tissue contours had developed.

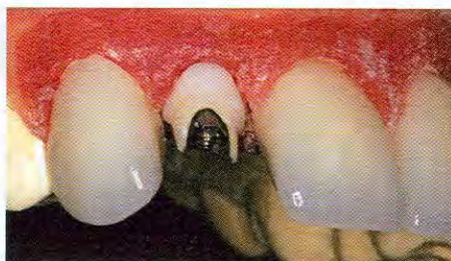

FIGURE 25 View of the laboratory cast with pressed ceramic coping.

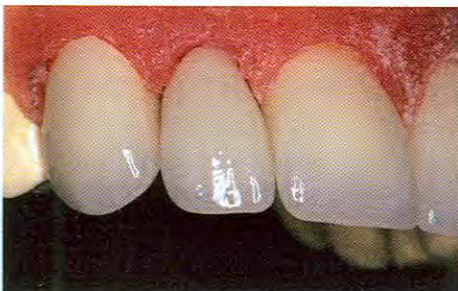

FIGURE 26 Laboratory view of the pressed ceramic coping and final all-ceramic restorations.

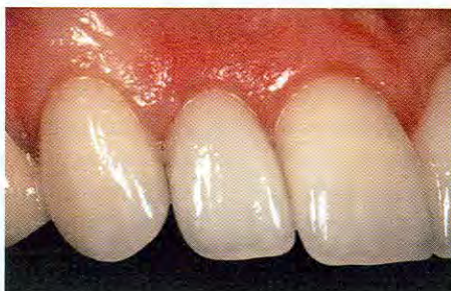

FIGURE 27 Final postoperative view of the restored right lateral incisor.

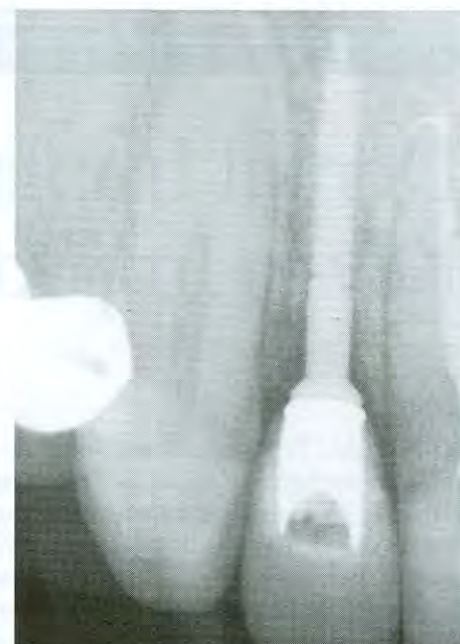

FIGURE 28 Digital periapical radiographic view upon case completion.

of dental implants, without preparation and/or reduction of the adjacent natural dentition. Proper placement procedures and restorative techniques can lead to very esthetic results, allowing for natural tissue contours and emergence profile formation that are reminiscent of the natural tooth.

ACKNOWLEDGEMENTS

The author would like to thank Mr. Edgar Jimenez of North Oaks, MN, for his excellence in the laboratory aspects of the cases presented, and Dr. Steven Boger of Hope, MN, for his excellence in restorative and cosmetic dentistry in the cases presented.

DISCLOSURE

Paul Petrunaro, DDS, MS, is a stock shareholder in Harvest Technologies and a consultant to Zimmer Dental.

REFERENCES

1. Branemark PI, Zarb GA, Albrektsson T. *Tissue-Integrated Prostheses: Osseointegration in Clinical Dentistry*. Chicago, IL: Quintessence; 1985.
2. Adell R, Lekholm U, Rockler B, et al. A 15-year study of osseointegrated implants in the treatment of the edentulous jaw. *Int J Oral Surg*. 1981;10:387-416.
3. Kan JY, Rungcharassaeng K. Immediate placement and provisionalization of maxillary anterior single implants: a surgical and prosthodontic rationale. *Pract Periodontics Aesthet Dent*. 2000;12:817-824.
4. Saadoun AP. Immediate implant placement and temporization in extraction and healing sites. *Compend Contin Educ Dent*. 2002;23:309-312, 314-316.
5. Petrunaro PS. Immediate implant placement and provisionalization in edentulous, extraction, and sinus grafted sites. *Compend Contin Educ Dent*. 2003;24:95-100, 103-104, 106.
6. Petrunaro PS. Immediate restoration of implants utilizing a flapless approach to preserve interdental tissue contours. *Pract Proced Aesthet Dent*. 2005;17:151-158.
7. Wohrle PS. Single-tooth replacement in the aesthetic zone with immediate provisionalization: fourteen consecutive case reports. *Pract Periodontics Aesthet Dent*. 1998;10:1107-1114.
8. Thompson VP, deRijik KW. Clinical evaluation and lifetime predictions for resin-bonded prosthesis. In: Anusavice KJ, ed. *Quality Evaluation of Dental Restorations: Criteria for Placement and Replacement; Proceedings of the International Symposium on Criteria for Placement and Replacement of Dental Restorations*. Chicago, IL: Quintessence Pub. Co.;1989:373-386.
9. Hansson O. Clinical results with resin-bonded prostheses and an adhesive cement. *Quintessence Int*. 1994;25:125-132.
10. Shugars DA, Bader JD, White BA, et al. Survival rates of teeth adjacent to treated and untreated posterior bounded edentulous spaces. *J Am Dent Assoc*. 1998;129:1089-1095.
11. Wallace SS. Significance of the 'biologic width' with respect to root-form implants. *Dent Implantol Update*. 1994;5:25-29.
12. Misch CE. Early bone loss etiology and its effect on treatment planning. *Dent Today*. 1996;15:44-51.
13. Salama H, Salama M, Garber D, et al. Developing optimal peri-implant papillae within the esthetic zone: guided soft tissue augmentation. *J Esthet Dent*. 1995;7:125-129.
14. Misch CE. Treatment options for a congenitally missing lateral incisor: a case report. *Dent Today*. 2004;23:90, 92, 94-95.
15. Petrunaro PS. Fixed temporization and bone-augmented ridge stabilization with transitional implants. *Pract Periodontics Aesthet Dent*. 1997;9:1071-1078.
16. Froum S, Emtiaz S, Bloom MJ, et al. The use of transitional implants for immediate fixed temporary prostheses in cases of implant restorations. *Pract Periodontics Aesthet Dent*. 1998;10:737-746.
17. Babbush CA. *Dental Implants: The Art and Science*. Philadelphia, PA: Saunders; 2001.
18. Andersson B, Odman P, Lindvall AM, et al. Single-tooth restorations supported by osseointegrated implants: results and experiences from a prospective study after 2 to 3 years. *Int J Oral Maxillofac Implants*. 1995;10:702-711.
19. Andersen E, Saxegaard E, Knutsen BM, et al. A prospective clinical study evaluating the safety and effectiveness of narrow-diameter threaded implants in the anterior region of the maxilla. *Int J Oral Maxillofac Implants*. 2001;16:217-224.
20. Davarpanah M, Martinez H, Tecucianu JE, et al. Small-diameter implants: indications and contraindications. *J Esthet Dent*. 2000;12:186-194.
21. Block MS, Delgado A, Fontenot MG. The effect of diameter and length of hydroxylapatite-coated dental implants on ultimate pullout force in dog alveolar bone. *J Oral Maxillofac Surg*. 1990;48:174-178.
22. Lazzara R, Siddiqui AA, Binon P, et al. Retrospective multicenter analysis of 3i endosseous dental implants placed over a five-year period. *Clin Oral Implants Res*. 1996;7:73-83.